



Paediatric stoma care

*Global best practice guidelines for
neonates, children and teenagers*

December 2018, Second edition



Content

Section A

Clinical aspects of paediatric stoma care

Chapter 1	Clinical aspects of paediatric stoma care.	6
Chapter 2	Common pathologies and indications for a stoma in neonates and children	8
Chapter 3	The types of stomas observed in paediatrics	12
Chapter 4	Skin characteristics of premature neonates, neonates and children	14
Chapter 5	Stoma site marking	14
Chapter 5	The basics of stoma care in neonates and children	16
Chapter 6	Paediatric stoma products and accessories	24
Chapter 7	Recognising, preventing and managing stoma, peristomal skin and systemic complications	30
Chapter 8	Perianal skin breakdown and diaper dermatitis post-stoma closure	40
Chapter 9	Anal dilation, incision and scar care management	43
Appendix	Educational tools references	44

Section B

Best practice guidelines for the psychosocial aspect of paediatric stoma care

Chapter 1	Best practice guidelines for the psychosocial aspect of paediatric stoma care	47
Chapter 2	Developing a therapeutic relationship with the child and family	48
Chapter 3	Adjusting stoma care education to meet the needs of the child and family	49
Chapter 4	The impact of stoma surgery on the child and family	56
Chapter 5	Daily activities with a stoma	66
Glossary	68

Paediatric stoma care

Global best practice guidelines for neonates, children and teenagers

These best practice guidelines governing paediatric stoma care are presented in two sections. The first section highlights the clinical aspects of paediatric stoma care. The second section addresses the psychosocial aspects of care, including stoma education and the emotional impact of a stoma on this patient group. The guidelines also include a glossary where you can find definitions for many of the terms used in the guidelines, and a list of additional resources that might prove helpful in treating this patient group. The guidelines cover the full spectrum of paediatric age groups, from neonates to teenagers.

Coloplast is the proud sponsor of the 'Global paediatric stoma care best practice guidelines, and has facilitated the process of creating this document. All content has been developed exclusively by the Global Paediatric Stoma Nurses Advisory Board (GPSNAB) with no involvement from Coloplast.

Introduction

People may be surprised to learn that children, babies and even premature neonates can have a stoma. Paediatric stoma care nursing is still a relatively undescribed field, and little literature and research are available. Many stoma care nurses working with adults say they would not be comfortable and confident caring for the paediatric population.

In order to provide more information about this area, we have brought together an international group of paediatric stoma care experts – the Global Paediatric Stoma Nurses Advisory Board (GPSNAB) – to develop global guidelines for healthcare professionals. These guidelines provide healthcare professionals working with the paediatric population with information concerning the basics of this speciality. This document covers everything from indications for a stoma and

the characteristics of neonatal skin and stoma care – to child and family education and the emotional impact of a stoma in children.

Paediatric stoma care is a science, but it is also an art that clinicians acquire over time. This expert group is dedicated to sharing the fruit of decades of experience as paediatric stoma nurses, to support healthcare professionals and ultimately improve the quality of life for neonates, children and teenagers with a stoma and their families.

It is therefore with great excitement that we present the Global Paediatric Stoma Care Best Practice Guidelines (GPSCBPG) and we hope you will find it useful.

The members of the Global Paediatric Stoma Nurses Advisory Board (GPSNAB)

The following specialists have been involved in developing these guidelines:

Louise Forest-Lalande	RN M. Ed NSWOC (Canada) GPSNAB Project Manager
June Amling	MSN RN CNS CWON CCRN (USA)
Claire Bohr	RSCN (United Kingdom)
Gail Creelman	RN NSWOC WOCC(C) Canada
Edith Ekkerman	RPN ET CT (The Netherlands)
Ester Sanchez Munoz	RN SEECIR (Spain)
Sophie Vercleyen	RN ET (France)

Stakeholder acknowledgement

The GPSNAB members acknowledge the following for their contribution in reviewing the Global Paediatric Stoma Care Best Practice Guidelines:

Astrid Ingeborg Austrheim	BSN RPN ET MBA (Norway)
Jane Fellows	MSN, RN, CWOCN-AP (USA)
Danila Maculotti	ET Nurse, Wound Care Specialist (Italy)
Lina Martins	RN, BScN, MScN, WOCC(C) (Canada)

Purpose and scope

The purpose of these guidelines is to provide a paediatric evidence-based central resource for best practice. It offers comprehensive information and recommendations for optimal stoma care delivery in the paediatric population.

The guidelines’ recommendations are based on literature and on the GPSNAB members’ experience. The guide is substantiated with references to provide credibility and evidence-based information.



Section A:

Clinical aspects of paediatric stoma care

In this first section of the guidelines, we focus on the clinical aspects of stoma care. We provide recommendations on;

- Common pathologies and indications for stomas in neonates and children.
- Types of stomas observed in paediatrics.
- Skin characteristics of premature neonates and children.
- Stoma site marking.
- The basics of stoma care in neonates and children.
- Paediatric stoma care products and accessories.
- Recognising, preventing and managing stoma, peristomal skin and systemic complications.
- Perianal skin breakdown and diaper dermatitis post-stoma closure; and
- Anal dilation, incision and scar care post-stoma closure.

At the end of this section, you will find a list of additional references, which you can consult if you're looking for more information on these areas.











Chapter 1:

Common pathologies and indications for a stoma in neonates and children

It is important to familiarise yourself with the common pathologies and indications for a stoma in neonates and children, as these are different than in adults. "There has been a decrease in the number of stoma performed in childhood with advances in surgical techniques and single-stage procedures..." (McIltrout, K.,

2016. p 174). The majority of the stoma surgeries performed in neonates and children are reversed, and the length of time with the stoma varies from a few months to a few years, depending on the diagnosis, the situation and the physician's practice.

Indications for faecal stoma in neonates and children. For further information see glossary





Congenital		
		
Anorectal malformation. Imperforate anus.	Cloacal exstrophy	Laparoschisis
		Read more in the glossary
Familial adenomatosis polyposis	Intestinal atresia: duodenal, jejunal, colonic	Hirschsprung's disease
Acquired		
		
Enterocolitis	Necrotising enterocolitis	Necrotising enterocolitis
		
Inflammatory bowel disease: Crohn's, Ulcerative colitis	Malrotation with midgut volvulus	


Indications for faecal stoma in neonates and children. For further information see glossary

Acquired		
Read more in the glossary	Read more in the glossary	Read more in the glossary
Meconium ileus	Tumour	A temporary diversion (colostomy) may be required in cases of severe perianal disease or trauma/wounds in the perianal area.
Read more in the glossary		
Complications of gastrointestinal surgery: Fistulae, abscesses, stenosis		

Motility		
Read more in the glossary		
Intestinal pseudo obstruction		

Indications for faecal stoma in neonates and children. For further information see glossary

Congenital		
		
Cloacal exstrophy	Prune Belly syndrome	Bladder exstrophy
		
Spina bifida		

Acquired		
	Read more in the glossary	
Hydronephrosis	Trauma	



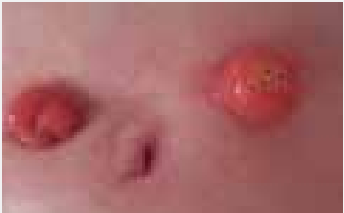


Chapter 2:

The types of stomas observed in paediatrics

As healthcare professionals, it is important that we are informed about the types of stomas that are observed in children, babies and neonates. The following chart provides examples and descriptions of the types of stomas observed in the paediatric population.

For more information, see the glossary.

Types of stomas

Faecal diversions		
		
End ileostomy/colostomy	Loop ileostomy/colostomy	End stoma with mucous fistula (either side by side or placed further apart)
Urinary diversions		
	Read more in the glossary	Read more in the glossary
Vesicostomies	Ileal conduit	Ureterostomies
Continence stomas		
	Read more in the glossary	
Mitrofanoff/Monti	Antegrade continence enema (MACE/ACE)	

Chapter 3:

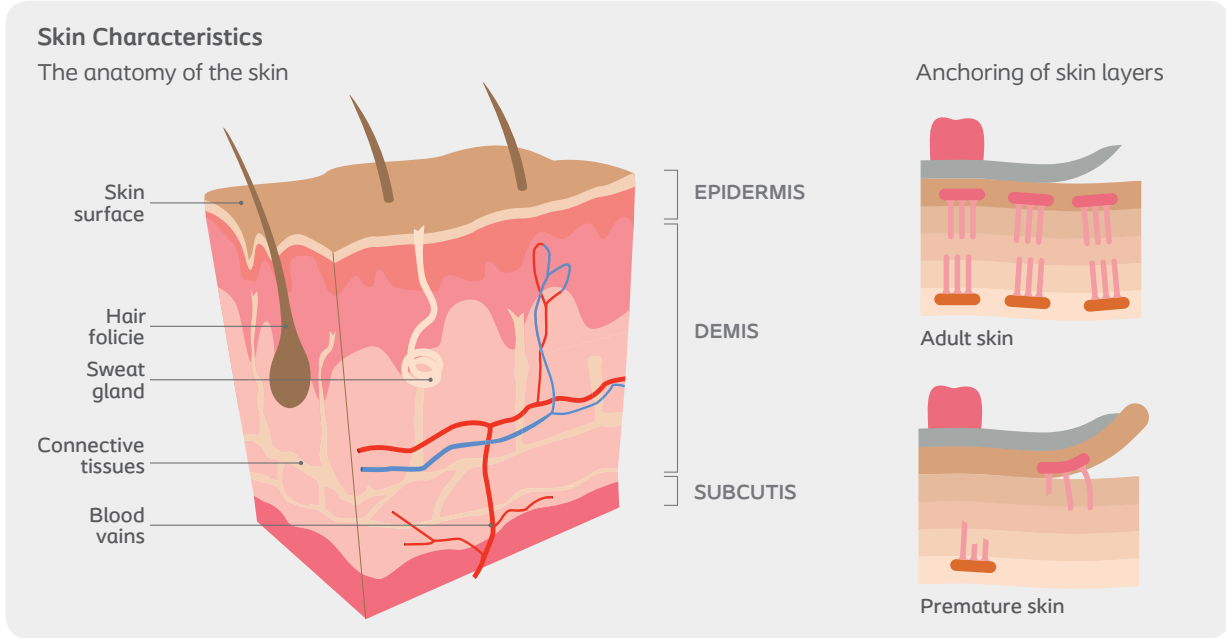
Skin characteristics of premature neonates, neonates and children

When treating the paediatric population, you need to familiarise yourself with the skin characteristics of this group. The skin of a premature neonate differs from that of the full-term neonate, child or adult. While adult skin has 15-20 cell layers, premature neonates have just a few cell layers, sometimes two to three, and sometimes none at all. Premature neonates are at greater risk of increased heat evaporation and trans-epidermal water loss (TEWL). The skin of a premature neonate is highly permeable, meaning that products applied on their skin may be absorbed into their system. For this reason, topical products, such as liquid skin barrier, adhesive remover, skin cement and benzoin should be avoided because of the risk of systemic toxicity.¹

Use these products only in extreme circumstances – when nothing else has worked or when the risk of not using these products outweighs the risk of using them. Always be cautious when using them on premature neonate skin.

What to be aware of
Any product containing alcohol should be avoided in premature neonates until their skin is mature enough to allow its use. However, infants of 37 weeks' gestational age show no drug transcutaneous absorption and have a good skin barrier function.² If there is a need to use a product such as chlorhexidine in a solution of alcohol, the skin should be promptly and thoroughly rinsed with sterile water afterwards. It is important to teach the caregivers to always check the components of any product they apply on the skin.

Research also shows that premature neonates present a diminished cohesion between the dermis and the epidermis that can lead to skin tearing when removing the skin barrier.³ This is why any skin barrier should ideally remain on the skin for at least 24 hours. We recommend keeping the barrier on the skin for up to 48 hours, after which it should be removed carefully.



1 AWHONN, 2007
2 Oranges T & al, 2015
3 AWHONN, 2007

Chapter 4:

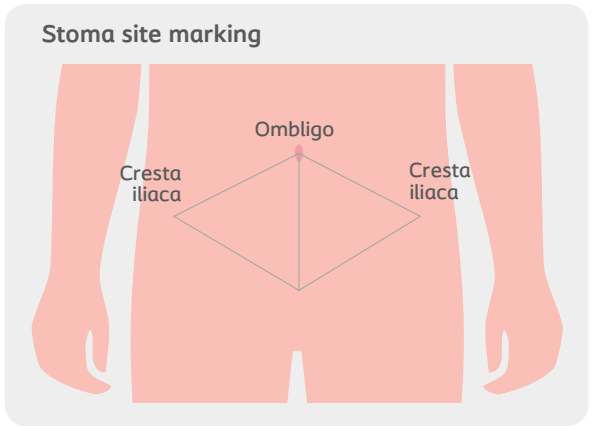
Stoma site marking

Stoma site marking is another important area within paediatric stoma care. Healthcare professionals need to be aware of when such marking is required, and when it is not. For example, when an infant undergoes stoma surgery, it is usually an emergency, and stoma marking cannot be arranged.⁴ However, stoma site marking is recommended in school-age children and teenagers with elective stoma surgery. This is to obtain the best seal in all positions.⁵ In case of elective surgeries, stoma site marking should also be considered, even for children younger than school-aged, to ensure quality of life with the stoma.

Factors impacting site selection
The same site selection criteria used for adults applies to the paediatric population. The challenge is, of course, that a smaller skin surface area is available. Depending on the age of the child, it is recommended that one parent is present at the time of stoma site marking, and that both the parent and child are included in the discussion of the site. When dealing with teenagers, make sure they have realistic expectations about what to expect when it comes to the final stoma location. For all patients, when a stoma is marked, the child and family should be advised that the site might be altered at the time of surgery according to intraoperative findings during the surgical procedure.

When marking the stoma site, remember to take into consideration the child's sporting activities, hobbies and clothing habits. Be sure to assess the child in various positions. Keep in mind that children with special needs (i.e. wheelchair bound) require special consideration when selecting the stoma site.

For emergency surgeries in neonates and premature neonates, it is important that the paediatric surgeon and the stoma nurse have a dialogue concerning the placement of the stoma. If possible, surgeons should avoid placing the stoma too close to the groin or the umbilicus. For more information, see Section A, Chapter 6 on Stoma care, pouch wear time for more information.



4 When an infant undergoes stoma surgery it is usually an emergency, and stoma marking cannot be arranged.» (Colwell JC & al, 2004 p.223).
5 Stoma site marking is, however, recommended in school-age children and teenagers with elective stoma surgery to obtain best seal in all positions. (WOCN Paediatric Ostomy Care: Best Practice for Clinicians p. 16)

Chapter 5:

The basics of stoma care in neonates and children

Adult stoma care principles apply to neonates and children. However, special attention should be given to the skin characteristics and body profile of premature neonates, neonates and children at various ages. This requires that stoma nurses always use their clinical judgement to provide the best practice in care.

The following factors must be assessed and documented when changing the stoma appliance:

- Stoma: size, protrusion (budded, flush or retracted below skin level), shape, colour, appearance
- Peristomal skin: intact, macerated, red, eroded, infected, allergic dermatitis, granuloma
- Muco-cutaneous junction: intact, separated
- Characteristics of effluents:
Stool: consistency, quantity, colour
Urine: clear, cloudy, with mucous, odour

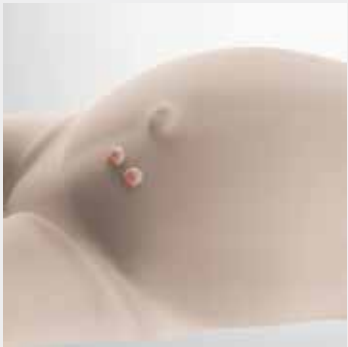Stoma care nurses should also document:

- Reason(s) for changing the pouching system
- In case of leakage, the area of the skin involved
- Reactions of the patient/parents/caregivers, i.e. level of comfort with stoma care
- Signs and symptoms of dehydration

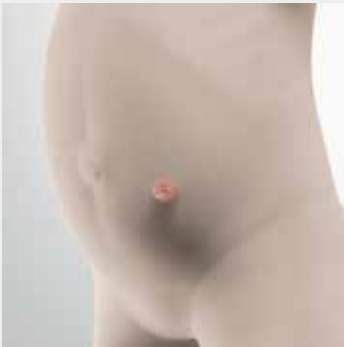Body profile

Babies usually have a short abdomen that is round, especially at the top portion. They have skin folds in the lower part of the abdomen near the groin, and there may be some friction between the pouch and the thigh when the baby is moving. These observations must be taken into consideration when selecting and applying a pouch to make sure that the stoma product does not interfere with the baby's mobility and comfort.

Body profile



Baby body profile with double barreled stoma



Toddler body profile

Use of convexity in neonates and children

According to literature, convexity should be avoided in newly formed stomas.⁶ The stoma nurse should make sure that the suture line of the stoma is healed before using any convexity, even a flexible one. In older babies and infants, the use of a flexible convex support can help to prevent leakage of stool or urine under the skin protective barrier.

Using a progressive convexity is recommended. For babies and infants, a convexity can be built using hydrocolloids and barrier rings. In toddlers, convexity can be created by adding pieces of barrier supplement, strips or rings to the wafer prior to application.⁷ In school age children and adolescents, a soft convexity paediatric stoma product can be used, if available.

Paediatric belts, which improve the efficiency of the convexity, are available. If you do not have these at your facility, you can either create one yourself, or adjust an adult stoma belt to fit the child, ensuring the buckles on the belt do not injure the skin.

Care of mucous fistula

According to literature, a mucous fistula may not require pouching, unless there is an associated discharge, or pouching is required to protect the stoma. In some cases, the fistula should be pouched separately from the functioning stoma. This is necessary if the stomas are spaced far enough apart on the abdomen, if a mucous fistula is present between the distal limb of the bowel and the urinary tract.⁸ To prevent the risk of a urinary tract infection, a urinary stoma should never be put in the same pouch as a digestive stoma.

Literature also states that the mucous fistula may be left uncovered within an infant's diaper, if it is placed lower than the functioning stoma and there is no risk of the infant handling the stoma. If the infant is particularly active, the fistula could become irritated or begin to bleed due to friction from the diaper. If this occurs, it may be necessary to cover the mucous fistula.⁹ When needed, the mucous fistula can be covered with a silicone dressing, a stoma cap, or with a neonate pouch. The covering can be left in place for several days, until it comes off or if leakage is observed. Ideally, the use of a transparent stoma product is recommended, so that the mucous fistula can be assessed daily.

Care of multiple stomas

Generally speaking, multiple intestinal stomas may be pouched within the same appliance.¹⁰ However, some precautions see Section A, Chapter 6, Stoma care; Care of mucous fistula.

Wear time of the stoma product

Keep in mind that the pouch wear-time for a pre-term infant is not comparable with that of an older child or an adult.¹¹ Considering that the premature neonate's skin has few cell layers and no or poor anchoring skin structures, the use of prolonged wear-time skin barriers can be detrimental to the skin of premature neonates and neonates. It is also important to avoid any product that increases the seal between the skin and the stoma product, such as cement or benzoin. Literature recommends that more frequent pouch changes may be preferable to ensure greater adhesion in the infant population and safeguard the infant's health.¹²

As mentioned at the outset of the guidelines, little evidence is available regarding paediatric stoma care. So be sure to incorporate available wound care evidence with stoma care. It is important to consider that:

- paediatric skin barriers are thinner to give them more flexibility, so they are less resistant to corrosive stool.
- neonates will spend most of their time in the supine position, so their skin is in constant contact with effluents.

The goal is to have the stoma product in place for a minimum of 24 hours to prevent disrupting the skin integrity due to poor anchoring structures, although with some poorly constructed stomas this may be a challenge. Erosion of the skin barrier should be observed daily to make sure that it still provides an adequate peristomal skin protection. If the skin barrier is still functional, the wear-time can be prolonged up to three days. Diet and positioning will affect the wear-time. «An infant ostomy appliance should be able to remain intact for at least 24 hours, or up to four days, with an average wear-time of two to three days. Wear-time decreases in premature infants, and acceptable wear-time may initially be 12 to 24 hours.» (WOCN Paediatric Ostomy Care p. 13)

Cutting of the stoma skin barrier opening

Evidence about the size to cut the actual skin barrier in neonates and children was not found in existing literature. However, we know it is important to check the size of the stoma with each pouch change for the first few weeks after surgery, because the size and

shape of the stoma may change as the oedema subsides. We are also aware that the size of the stoma will change over time as the baby/child grows, so regular measurements of the stoma are needed. The protective skin barriers available today are more malleable and less likely to cut into the stoma. If cut larger than the stoma, the peristomal skin is exposed to the effluent, which may lead to leakage and skin breakdown. Literature recommends that the stoma opening should be no more than 1/8-inch (1-2mm) in diameter larger than the stoma diameter at skin level. This is to minimise the skin's exposure to effluent. The stoma opening should likewise be no less than equal to the stoma diameter to prevent trauma to the stoma or obstruction of its opening.¹³ If the opening of the skin barrier leaves an area where the skin is exposed, we recommend using stoma paste or a ring.

In case of a prolapsed or mushroomed stoma, it may be difficult to measure the stoma base adequately. To ensure the peristomal skin is well protected by the skin barrier, the stoma must be gently lifted up to facilitate a correct measurement.

Dealing with a mushroomed or prolapsed stoma
It can also be a challenge to insert a prolapsed stoma in a pouch without causing any trauma to the skin. To make this insertion easier you can:

- use a skin barrier ring, either in its original shape or flatten and stretch it to make a wider barrier. This will allow the opening of the collaborative team approach skin barrier to be cut larger to accommodate the prolapsed/mushroomed stoma.
- cut radial slits around the opening of the skin barrier to make it easier to slip the pouch over the mushroomed/prolapsed stoma. Then the skin barrier can be flattened down around the base of the stoma.

Peristomal skin cleansing
Cleanse the stoma and peristomal skin using luke-warm water and a soft cloth. The skin should be patted dry gently without any friction. Avoid using commercial wipes, as these may contain additives that can cause skin irritation or allergies. Use a non-sterile soft cloth instead. Products containing oil, lanolin or natural commercial oils are also discouraged, as they will interfere with the adhesion of the stoma product.

Emptying the pouch
The pouch should be emptied when it is 1/3 full, which can be quite often in babies. This is because they evacuate a large amount of stool and their pouches are small. If the frequency of emptying the

pouch is high, consider using a small adult drainable pouch. If the infant has a urinary stoma, use a drainage bag overnight.

Gas
It is normal for babies to produce more gas than adults. They swallow air during sucking, and assisted ventilation produces extra air. Parents should be taught how to remove gas from the pouch. Some stoma pouches come with a filter. In other cases, the pouch can be opened up, or a vent can be added to the pouch to release the gas.

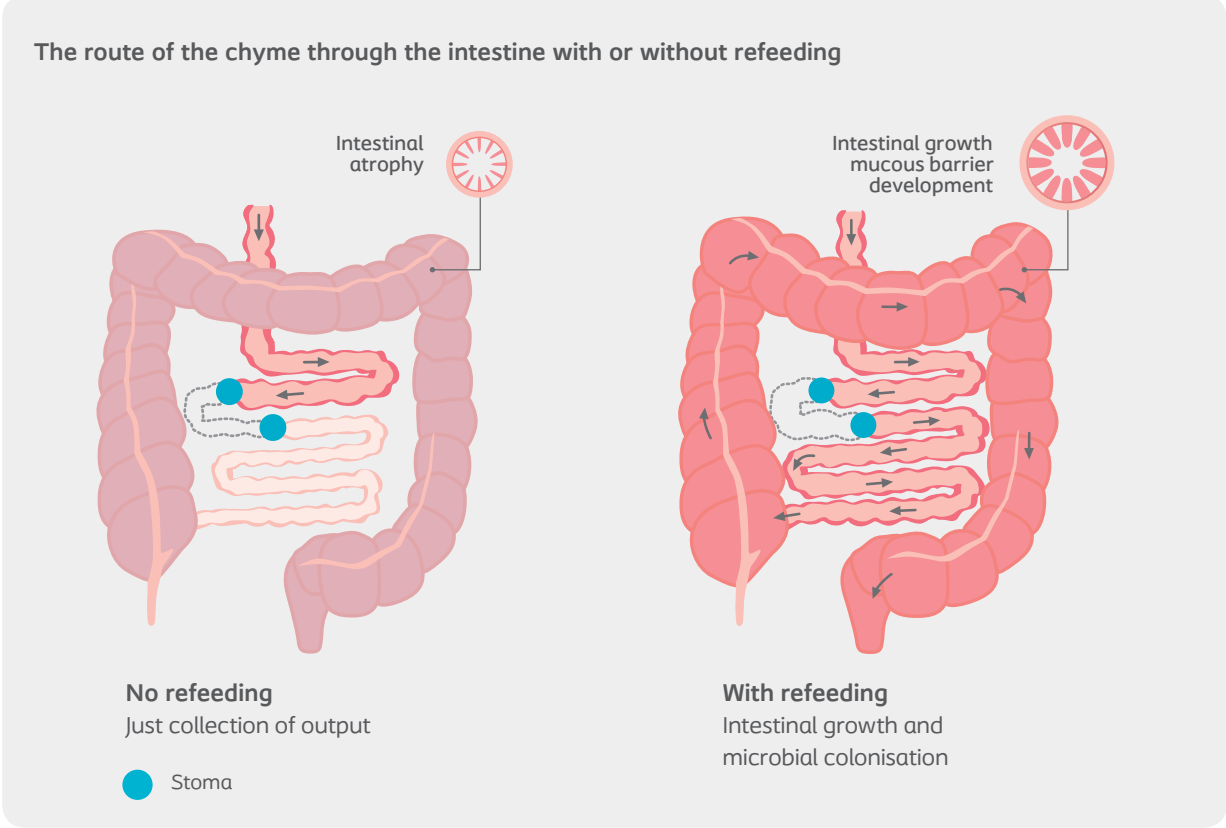
Rectal discharge
Parents (and the child, if appropriate) should be advised that it is normal to have some rectal discharge. This can be due to:

- The distal bowel expelling the stool left over in it after the stoma was surgically created;
- The distal bowel wall continuing to produce mucous, which is periodically expelled from the rectum;¹⁴
- Diversion colitis, which is an inflammation of the non-functional bowel. This condition may cause a dark or foul-smelling rectal discharge; or¹⁴
- A loop stoma that does not divert stool completely. In these cases, spill over from the proximal to the distal bowel results in stool passage from the rectum.¹⁴

In older children, it may be necessary to irrigate the rectum or mucous fistula, depending on the amount of mucus being produced. This is done with a fluid prescribed by the doctor or stoma nurse.

Mucous fistula refeeding (MFR)
The practice of mucous fistula refeeding (MFR) is still controversial and practices varies from one health-care centre to another. Due to the risk of complications, it is recommended that this procedure be implemented in specialised centres.¹⁵ It is important that you familiarise yourself with the protocol in your institution when practising MFR. Optimal care and management of MFR is achieved by using an evidence-based, and collaborative team approach. The institution must also have a thorough understanding of the technique and supplies to be used.

Definition and indications
«MFR involves the introduction of proximal enterostomy effluent into the mucous fistula (distal loop), so as to mimic the complete physiological pathway that normal intestinal content will go through.»¹⁶
MFR is indicated for patients with short bowel syndrome (SBS) to prevent fluid and electrolyte im-



balance and parenteral nutrition (PN) complications, while maximising growth.

Benefits and complications
The MFR procedure comes with benefits as well as potential complications.

Benefits:

- Maximises absorption of nutrients and assists with reabsorption of water and electrolytes
- Decreases or eliminates the need for parenteral nutrition (PN).
- Stimulates intestinal activity at the distal portion of the bowel to minimise the discrepancy in lumen size between the two ends, in this way preventing anastomotic complications such as stricture and leakage.

Potential complications:

- Perforation of the bowel.
- Intolerance of refeeding.
- Skin irritation around mucous fistula (MF).
- Difficulty keeping tube/catheter secured in mucous fistula.

Candidates for MFR
The attending paediatric surgeon is the health care professional determining whether or not the infant or child is a candidate for the MFR procedure. Typical

candidates will be patients who have one or more of the following symptoms/characteristics:

- An ileostomy or jejunostomy and a mucous fistula;
- Substantial length of bowel distal to the primary ileostomy/jejunostomy;
- Stable systemically;
- Not gained weight with optimal calories through enteral feeds; or
- An established enteral feeding program.

The MFR technique
Collection of effluent:

- Collect effluent from proximal stoma using a drainable pouch
- Use of skin barrier paste or powder is not recommended as these can become mixed with the effluent.
- If MF is close to the proximal stoma, it can be included in the same pouch.¹⁷ However, there is a risk of the feeds going into the MF draining back into the pouch unnoticed.

Delivery of effluent:

- The initial tube/catheter should be inserted by the surgeon.
- A 6-8 Fr tube (Feeding or indwelling catheter) is advanced in the MF for a distance of ideally about 5 cm, depending on ease of insertion.¹⁸

- The tube can sometimes be inserted up to 10 cm; however, it is the paediatric surgeon who makes the final decision on insertion length.
- Size of the tube may vary according to the size of the baby, the size of the MF and the consistency of the effluent. The surgeon decides on the type and size of the tube.¹⁷
- If you use an indwelling catheter, the amount of sterile water used to inflate the balloon should be selected by the surgeon. Usually indwelling tubes are inflated with 1-2 ml of sterile water.
- Ensure that inflating the balloon does not obstruct the distal bowel.
- If the tube/catheter was inserted without difficulty, then it can be reinserted by a stoma-trained nurse or bedside nurse.¹⁹ However, fewer complications were observed in facilities where only the surgeon can place or replace the tube/catheter.²⁰

Securement of tube:

- A secure fixation of the tube/catheter is mandatory to prevent any dislodgement.
- Different fixation techniques can be used:
 - The tube/catheter may be secured by placing it through a stoma appliance and taping it securely to the pouch.
 - It can be secured between the pouch and skin barrier. If this technique is used, you need to vary the location where the tube/catheter is secured with each pouch change. This decreases the risk of trauma to the MF.
- A third option is to use commercial fixation devices.

Refeeding:

- The refeeding rate is prescribed by the paediatric surgeon/gastrointestinal doctor. Lau recommends a rate not exceeding 6 ml/h and hypothesises that this rate helps to maintain the MF with sufficient stimulation, while avoiding overloading.²⁰
- The infusion rate is gradually increased until it ideally matches the total proximal output.²⁰
- Effluent is collected every 4 hours. Collections are coordinated with handling times of the infant.
- Use a syringe to drain the stoma pouch.^{17,20}
- The collected effluent is delivered in the MF using a syringe pump that has been programmed to deliver the effluent over the following 4 hours. Small volumes can be delivered slowly manually by syringe.¹⁷

Precautions:

- Before refeeding, all patients need to have a lower gastrointestinal series to rule out stricture or obstruction of the distal bowel that would interfere with refeeding.²¹
- Clearly identify the infusion pump and tubing to prevent errors in connecting to the wrong system (Enteral feeds, IV)
- Monitor the stoma site for signs of irritation, laceration, prolapse or necrosis.²²
- Assess and care for the skin around the stoma and the MF to avoid irritation or skin breakdown due to leakage.²¹
- Carefully measure the effluent and monitor it for a milky or undigested appearance.²¹
- Closely monitor the infant’s weight, head circumference, length, stoma losses, serum electrolytes, blood gases and liver function tests.²¹
- Monitor rectal output.
- Check urine weekly for sodium and potassium levels.
- Assess for signs of intolerance such as discomfort, distension.
- Change the tube according to the hospital policy and physician preference.

In summary, literature concludes that MFR “...is safe, and can decrease the risk of anastomotic complication and parenteral nutrition-related cholestasis. It provides both diagnostic and therapeutic value and its use should be advocated.”¹⁸ However, stringent guidelines need to be in place for intubation of the MF and the method of feeding delivery.²³

For more information, please go to:
http://policy.nshealth.ca/site_published/iwk/document_render.aspx?documentRender.IdType=6&documentRender.GenericField=&documentRender.Id=50846

Vesicostomies

Vesicostomies are difficult stomas to pouch because of their location in the very lower part of the abdomen (they are commonly placed in the middle of skin creases). Vesicostomies are usually reversed before the age of 2.5-3 years, so the child can be potty-trained. If not reversed before the child is 4-5 years of age, the stoma nurse may help to find a way to contain urine.

Vesicostomies can be managed with diapers, but they usually cause leakage problems. To address this, place the diaper on backwards, as the back portion will extend further up over abdomen.

Skin breakdown is common with vesicostomies, and the child is especially prone to fungal infections. Continue to use antifungal cream/powder for seven days after the disappearance of clinical signs. It is important to inform parents about the clinical signs of infection and how to apply antifungal products.





A vesicostomy usually drains continuously. The absence of drainage may be a sign of stenosis; parents must be made aware of this complication and that they should contact the stoma nurse/physician if such a situation is observed.

Challenges unique to paediatrics



The following chart outlines some challenges that are unique to paediatric stoma care, as well as our recommendations on how to address these challenges.

6 WOCN PEDIATRIC OSTOMY CARE: Best Practice for Clinicians, 2011, p. 20
7 «Convexity can be created by adding pieces of barrier supplement/strips/rings to the wafer before it is applied» (WOCN PEDIATRIC OSTOMY CARE: Best Practice for Clinicians, 2011).
8 WOCN Pediatric Ostomy Care: Best Practice for Clinicians p. 27
9 WOCN Pediatric Ostomy Care: Best Practice for Clinicians p. 27
10 WOCN Pediatric Ostomy Care: Best Practice for Clinicians p. 24
11 Rogers V Managing Preemie stomas: More Than Just the Pouch JWOCN 2003:30 p. 108)
12 WOCN Paediatric Ostomy Care p. 41
13 WOCN Paediatric Ostomy Care p.24
14 WOCN Pediatric Ostomy Care, p. 7
15 Richardson, 2006
16 Lau et al, Beneficial effects of mucous fistula refeeding in necrotizing enterocolitis neonates with enterostomies. Journal of Pediatric Surgery 51 (2016) p. 1914
17 http://extcontent.covenanthealth.ca/Policy/Enterostomy_Refeeding.pdf
18 Al-Harbi et al., 1999
19 Haddock, 2015
20 Lau, 2016
21 (Al-Harbi & al Mucous refeeding in neonates with short bowel syndrome. Journal of Pediatric Surgery, Vol 34, No 7 (July), 1999: p 1100)
22 http://extcontent.covenanthealth.ca/Policy/Enterostomy_Refeeding.pdf
23 Haddock et al, 2015

Challenges with faecal stomas in neonates and children

Challenges	Recommendations
Stoma close to or within intact incision	If the incision is closed and no signs of infection are observed, the skin barrier can be applied over it.
	The wound should be managed as any other wound according to wound care principles and covered with a dressing, e.g. a thin hydrocolloid. If there is leakage, an absorbent dressing covered with a thin hydrocolloid or a transparent dressing can be used. The stoma product can be applied on top of the dressing.
Stoma close or within an incision/wound	
	Off-centre the skin barrier opening. If there is a starter hole, cover it with a thin hydrocolloid dressing to prevent any exposure of the skin to effluent. Trim the skin barrier to accommodate the umbilicus.
Stoma close to umbilicus	
	Cover central IV lines to avoid contamination (e.g. with a transparent dressing or a central IV line protector). Commercial central IV lines protectors have been developed.
Stoma close to central IV lines	
Size of neonates	Create a customised pouching system.
Activity level of the child, crawling, jumping, playing, easy disengagement and accidental removal	One-piece outfits, onesies, hairband, sash
	When it is absolutely impossible to maintain a stoma product on the skin, it is recommended to protect the peristomal skin with a thick layer of zinc-oxide paste. Collect the stool with fluffy gauzes and change them when soiled. Dimethicone-based products can also be used, but in the case of neonates it is important to make sure that the skin is mature and not permeable to any noxious substance contained in the product. When the suture line and/or skin is healed, a flexible convexity can be used. (Ref to Use of convexity in children, p.XX)
Skin level stoma opening	

Challenges with faecal stomas in neonates and children

Challenges	Recommendations
	Refer to chapter 6. Care of multiple stomas.
Multiple stomas	
Skin becoming oily from oral supplements given to infants.	Some children, especially those with cystic fibrosis, may have oily skin that can interfere with stoma product adhesion. Tip: Cleanse the skin well. Put a small amount of stoma powder on the skin, and apply the pouch. The use of a medical adhesive may be necessary. Expect a shorter pouch wear-time.
	When the baby/child is lying down, the pouch should be applied with the drain opening to the side. This makes it easier to put it outside the diaper and to empty. This will also prevent the pouch lying on the thigh and makes it easily accessible if the baby is in an incubator. Although sometimes necessary, folding the pouch should be avoided, as it will reduce its efficiency.
Stoma product and diaper: in or out?	For toddlers and older children, the pouch should be applied vertically. This allows for easy emptying when the child sits on the commode. It is also helpful to position the pouch vertically when a belt is used, as the belt loops on the pouch are positioned at 3 and 9 o'clock.

Chapter 6:

Paediatric stoma products and accessories

Today, there are more paediatric stoma products available than ever before. However, the selection is still limited in neonates, as well as for children with high or liquid output, and/or a difficult location. For this reason, healthcare professionals working in paediatrics must be imaginative and creative. Often, we have to create what does not exist. Here, advocacy work is important. We need to speak for neonates and children with stomas and share our experiences with others in the healthcare industry. This is the only way to improve quality of care through creating more user-friendly products.

Selecting the right stoma care product

When selecting a stoma product, there are a number of factors that need to be considered:

- Child's age, weight and surface of the abdomen;

- Location of the stoma;
- Type of stoma (Urostomy, ileostomy, colostomy);
- Protruding, flat or retracted stoma;
- Proximity and functionality of other stomas;
- Consistency and daily volume of the effluent. (In the case of liquid stool, a urostomy pouch can be used.);
- Body profile; and
- Child's mobility/activity.

Products containing latex should always be avoided. It should also be noted that a six-month-old baby who produces a lot of stool might need a small adult pouch attached to a paediatric skin barrier. It may even be necessary to use an adult skin barrier, if a larger adhesion area is needed.

Product selection guide for faecal stomas

Stoma products	Benefits/Tips	Precautions
Drainable paediatric one-piece pouch	In newborn and premature babies, one-piece drainable systems are most common.	Warm the skin barrier with your hands.
Drainable newborn one-piece pouch	When flexibility is needed.	No product should be heated with an air dryer or external heat source.
Drainable premature neonate one-piece pouch	Also used with low-profile stomas.	
	Recommended when there are too many dips and creases on the abdomen.	
Two-piece: <ul style="list-style-type: none">• Coupling can be standard or adhesive.• Pouch can be drainable or closed.		
Paediatric stoma pouch	Active toddlers	When there is a prolapse, be careful not to hurt the stoma when using a two-piece stoma product.
Skin barrier	Access to a belt	Pouch should always be applied on a skin barrier, not directly on the skin.
	Easier visualisation of the stoma.	
	It is simpler for children at school to change a two-piece bag, than to try to empty stool from a drainable one.	
	Useful when stool samples must be collected.	To prevent injuries, avoid devices with hard plastic closures.

Product selection guide for urinary stomas

Stoma products	Benefits/Tip	Precautions
One-piece urostomy pouch	May be connected to overnight bag.	Urinary pouch may be blocked with mucus (ileal conduit). To prevent this, you can: <ul style="list-style-type: none">• increase fluid intake.• acidify urine by giving the child cranberry juice and vitamin C supplements. Citrus fruits drinks should be avoided because they have an alkaline residue once metabolised.
Two-piece urostomy pouch	May be connected to overnight bag.	

Removal of stoma products

In order to prevent any skin irritation or damage, removal of the stoma product should be done gently. Sprinkling stoma powder on the area will limit the friction/pressure needed to remove the paste or the barrier rings. The skin should be cleansed thoroughly as recommended by the facility.

Remove the pouch using a gauze and lukewarm water. Gently peel it off. Removal wipes containing alcohol or any other substances should be used with caution in premature neonates, neonates and children, because they may contain noxious substances or may generate allergic reactions. Literature recommends that you limit the use of adhesive remover in infants to situations where: a) the epidermis would be

damaged if a remover was not used; and b) removal cannot be postponed.²⁴ Sprays should also be used with caution, as they can be detrimental to babies' and children's pulmonary system.

Skin barrier starter hole

In neonates and children, it is more convenient to use a skin barrier without a starter hole. This gives more versatility when a tube, a wound, another stoma or a mucous fistula is close to the stoma to be pouched. If there is a starter hole, it can be off-centred and a thin hydrocolloid dressing should be applied to make sure no skin is in contact with stool or urine. In the case of multiple stomas, a thin hydrocolloid may be used to make a base for a custom fit product.

Accessories selection guide

Stoma products	Benefits/Tips	Precautions
Stoma paste	<p>Residual stoma paste and hydrocolloid usually do not interfere with the adhesion of new stoma product.</p> <p>To remove paste residue, stoma powder can be sprinkled on the residual paste to facilitate its removal.</p>	<p>Avoid stoma paste containing alcohol in premature neonates.</p> <p>Stoma paste can be put into a 5 ml syringe to control the amount of paste applied on the skin barrier.</p> <p>It is preferable to apply the stoma paste on the skin barrier rather than on the peristomal skin. This is because, when applied directly on the skin, the result will be a mixture of stoma paste and stool if the stoma is functioning. And if this happens, you will have to clean it up and start again.</p>
Pouch deodorizer	Neutralizes odour.	<p>Not recommended for neonates and children.</p> <p>Much appreciated by teenagers.</p> <p>Can be homemade. Example: apply toothpaste on toilet paper and insert at the base of the pouch.</p>
Stoma pouch lubricant	Aids emptying the pouch.	<p>Rarely used in children.</p> <p>A little bit of oil can also help emptying the pouch.</p>

Accessories selection guide

Stoma products	Benefits/Tips	Precautions
Stoma powder	<p>Used to perform crusting technique.</p> <p>Dries moist skin.</p> <p>Can be mixed with stoma paste to increase absorptive properties.</p>	<p>If there is a problem removing stoma paste, sprinkling stoma powder on it makes it easier to remove.</p> <p>Can be fixed with dabs of water.</p> <p>Crusting technique: fix with non-alcohol liquid skin protector.</p> <p>Caution: protect the neonate's and child's face to prevent inhalation of the powder.</p>
Hydrocolloid dressing	Can serve as a base for a custom fit product.	Thin hydrocolloid is recommended. It should ideally stay on the skin for 24 hours.
Thickening gel capsules/tablets	Thickens watery faeces in the pouch.	<p>Bits of disposable diaper lining containing absorbent gel materials can be placed in the pouch to absorb excess liquid from the effluent.²⁷</p> <p>Cotton balls can also be placed in the pouch to absorb liquid effluent.</p>
Mouldable ring/strip (hydrocolloid)	<p>May be used to create flexible convexities, fill creases and skin folds or to make the peristomal plane even.</p> <p>Easier to work with when pre-warmed.²⁸</p> <p>Alcohol-free.</p>	<p>Heat with your hands.</p> <p>Caution: Warming under a radiant warmer may overheat the barrier and damage peristomal skin.²⁷</p>
Hernia binder	<p>Supports parastomal hernia.</p> <p>Can be handmade Ref. to complications: Parastomal hernia. Section A, chapter 7, page 35</p>	
Convexity	<p>Increases stoma protrusion</p> <p>Can be created with mouldable rings or strips of skin barriers.</p> <p>A soft convexity paediatric stoma product can be used if available.</p>	<p>Mucocutaneous area must be healed.</p> <p>May cause peristomal skin pressure ulcer. Use with caution in case of peristomal hernia.</p>

Accessories selection guide

Stoma products	Benefits/Tips	Precautions
Filter	Facilitates the expulsion of gas.	Liquid stool may compromise the action of the filter. The filter needs to be protected at the time of bath/shower.
Leg bag/night drainage collectors	Leg bag can be used in the case of nephrostomy. Urinary diversions: Collects urine overnight so the child/family get a better night's sleep. High-output stomas: Prevents premature or accidental dislodgement of the stoma product.	Check for the patency of the tubing to make sure that there is no obstruction to the elimination of urine.
Elastic barrier strips	Secure the position of the skin barrier.	Can be used to secure the skin barrier when swimming or doing sports.

24 WOCN Pediatric Ostomy Care, p. 42
25 WOCN, 2011
26 WOCN 2011, p.49
27 WOCN 2011, p.49
28 WOCN p. 43



Chapter 7:

Recognising, preventing and managing stoma, peristomal skin and systemic complications

Stoma and peristomal skin complications are also observed in neonates and children, and it is imperative to know how to manage them.



Risk factors influencing stoma and peristomal complications include:

- immature neonate skin; See Section A, Chapter 3. Skin characteristics of premature neonates, neonates and children;
- underdevelopment of abdominal musculature may lead to peristomal hernia;
- poor siting and stoma construction. This is especially the case with neonates, as surgery is emergent and often in unfavourable conditions.



Definitions

Urgent action required	Child must be referred to the stoma nurse or surgeon urgently.
Needs review	The problem can be solved easily but needs a follow-up.
Non-urgent	There is a problem needing to be addressed but not urgently.




Stoma complications

Complications	Description	Management	Precautions
Haemorrhage	Blood is coming from the opening of the stoma.	Consult the surgeon or the stoma nurse urgently.	
	Persistent necrotic tissue is observed suggesting that the fascia is affected.	When the fascia is affected, a second operation is necessary. ³¹	
Total necrosis			
Read more in the glossary	Total separation of the stoma at the suture line.	Urgent, call the surgeon.	Risk of peritonitis.
Total mucocutaneous separation			
	Stoma is at skin or below skin level and may be secondary to excessive tension of the mesentery. The depth of retraction may increase when the patient is seated. ³⁵ Related factors: Short mesentery, rapid weight gain, obesity, surgical technique, excessive tension in the suture at the fascia level, malnutrition, immunosuppression. ³⁶ In neonates, abdominal distension may cause this complication.	Creation of a flexible convexity, if the suture line is healed. If the stoma is in a deep crease, use a flexible one-piece stoma product. When it is impossible to keep a stoma product on the skin and the peristomal skin cannot be protected appropriately, refer to the surgeon to know if it is possible to modify or reverse the stoma. Depending on the length of time the stoma will be needed, closure of the stoma may solve the problem. In cases of long-term stomas, re-operation may be necessary. If unable to apply pouch, protect the peristomal skin and collect the effluent with fluffy gauzes or other absorbent product.	
Flat or retracted stoma			


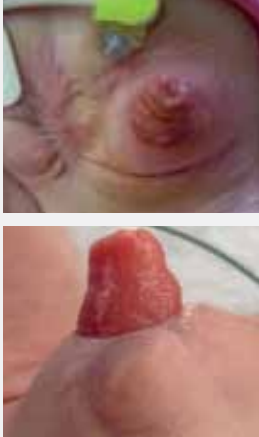


Stoma complications

Complications	Description	Management	Precautions
Blockage	<ul style="list-style-type: none">• Mostly seen with ileostomies• Less or no stool in the pouch• Change of stool consistency that may be liquid• Abdominal distension• Abdominal cramping• Oedema of the stoma• Nausea• Vomiting <p>May be secondary to high fibre or high residue food that has not been chewed enough.</p>	<p>Monitor closely and seek medical advice if:</p> <ul style="list-style-type: none">• symptoms aggravate;• the child goes more than 8- 12 hours without stools, or; there is a change from normal output.• the child is vomiting. <p>Modify opening of the skin barrier in case of stoma oedema.</p> <p>Abdomen massage. Warm bath.</p> <p>Dilation of the stoma.</p> <p>Irrigation of the bowel under physician's order.</p> <p>Education.</p>	
<p>Read more in the glossary</p>	Abnormal connection between two epithelium-lined surfaces.	<p>Conservative management if no stoma pouch can stay on long enough:</p> <ul style="list-style-type: none">• Zinc oxide + fluffy gauze to be changed when soiled.• Surrounding skin can be protected with a thin hydrocolloid or a no-sting liquid skin protector.	
Fistulas			
			
Multiple fistulas			
	Painful ulcerations frequently associated to Crohn's disease.	<p>Must be referred to the gastro-enterologist for systemic therapy.</p> <p>Topical treatment:</p> <ul style="list-style-type: none">• Tacrolimus ointment• Hydrocortisone• Absorbent dressing under stoma product	This skin problem may also be observed in other body parts (e.g., inguinal fold).
Pyoderma gangrenosum			
Loss of epithelium, irregular borders, bleeding and pus, pain, difficulty to maintain appliance adherence.			


Stoma complications

Complications	Description	Management	Precautions
 Stenosis (Urinary stoma)	<p>Narrowing of the stoma at skin or fascia level.</p> <p>Usually secondary to peristomal skin hyperplasia.</p>	<p>Dilation or surgical revision.</p> <p>Check the cutting technique to make sure that the opening is not cut too large.</p> <p>Educate parents/caregivers about proper cutting technique.</p> <p>Refer to Hyperplasia.</p>	<p>Check that the stoma is adequately functioning.</p>
 Overgranulation	<p>Overgrowth of the stoma tissue due to excessive exposure to effluent.³² This occurs more frequently in young patients and those with urostomies less than one cm wide.³³</p> <p>An inaccurate opening or ill-fitting stoma pouch can lead to leakage or abrasion to the muco-cutaneous junction. These can make the skin susceptible to granuloma formation.³⁴</p>	<p>Optimise device adjustment to minimise trauma and contact with effluent.</p> <p>Careful cleansing because of associated pain.</p> <p>Treatment: Apply silver nitrate for 5 seconds. Treat once a week for 4 weeks. Commercial tape impregnated with steroid fludroxycortide can be used to treat the granuloma. It is ideal to apply under the stoma product as the pouch will adhere to the tape.</p>	<p>Overgrowth tissue may bleed during the stoma hygiene and stoma product change. It is advisable to take extreme care during these manoeuvres.</p>
 Partial necrosis	<p>Grey, dark brown or black discoloration of all or part of the stoma due to:</p> <ul style="list-style-type: none">- inadequate blood supply - excessive dissection of the mesentery.- traction of the mesentery.- major oedema of the bowel. <p>Stoma is dry and firm.</p> <p>Evolution:</p> <p>The necrotic tissue becomes thinner, sloughs and may produce an unpleasant odour.</p>	<p>The degree of necrosis is variable and can be assessed by passing a small, lubricated glass tube into the stoma and inspecting the mucosa with a pen light.³⁰ This technique depends on the size of the stoma, and should be carried out under the supervision of the surgeon. Plastic tubes can also be used ,if available.</p> <p>Usually the necrotic tissue debrides spontaneously with time. As long as the stoma is patent and healthy at the base, no further debridement is required.</p>	



Stoma complications

Complications	Description	Management	Precautions
 <p>Laceration of the stoma</p>	<p>Appears as white, ulcer-like markings on the stoma.</p> <p>Possibly due to trauma or ill-fitting stoma product.</p> <p>Also occurs as the result of very active toddlers.</p> <p>Poor cutting technique.</p>	<p>Check the cutting technique. Educate parents/caregivers.</p> <p>Haemostasis (gentle compression) if bleeding.</p> <p>Apply stoma powder on the cut to support healing.</p>	<p>Ensure there are no sharp edges on the skin barrier.</p>
 <p>Parastomal hernia</p>	<p>Defect in the fascia that allows loops of intestine to protrude into the area of weakness.³⁷</p> <p>Aggravated by increased abdominal pressure (e.g., crying).</p>	<p>One-piece pouching system or two-piece with a floating flange.</p> <p>Feather/petal the barrier for more flexibility.</p>  <p>Creative hernia belts</p>	<p>Since the stoma is usually temporary, re-operation is usually not considered.</p> <p>However, it is important to check for any signs of complications, such as:</p> <ul style="list-style-type: none"> • stoma patency. • change in colour; or • discomfort.
<p>Read more in the glossary</p> <p>Suture granuloma; multiple granulomas</p>	<p>Inflammatory reaction often secondary to suture material.</p> <p>The granuloma may bleed and be painful.</p>	<p>This can be treated in three ways:</p> <ul style="list-style-type: none"> • Use of silver nitrate application(s) to granuloma(s); • Use of a steroid tape applied under the stoma product; or • Excision of suture material with the surgeon's approval. 	
 <p>Partial mucocutaneous separation</p>	<p>Partial separation of the stoma at the suture line, caused by:</p> <ul style="list-style-type: none"> • poor healing; • tension; • infection; or • surgical technique. 	<p>In case of leakage, fill the defect with an absorbent dressing (i.e. powder, mixture of powder and stoma paste, wound paste, hydrofiber, calcium alginate) and apply the stoma product.</p> <p>The skin barrier is applied on top of the dressing. In some cases, a transparent dressing or a thin hydrocolloid product can be applied over the wound before applying the stoma product.</p>	<p>Monitor and document the evolution of the separation. If healing is delayed notify the surgeon.</p>



Stoma complications

Complications	Description	Management	Precautions
 <p>Peristomal skin fungal infection. Papules, redness and satellites lesions are observed, the skin is itchy and burning.</p>	<p>The most common cause of fungal infection in patients with stomas is the overgrowth of a <i>Candida</i> (usually <i>C. Albicans</i>)</p> <ul style="list-style-type: none"> • Pustules or papules • Diffuse erythema maceration • Satellite lesions • Pruritus and burning sensation around the stoma. 	<p>Take a complete patient history.</p> <p>Identify and correct the cause.</p> <p>Check the stoma product to make sure that it fits well to prevent leakage.</p> <p>Prevention: Thoroughly dry the skin before applying the pouch.</p> <p>After bathing with a pouch on, towel dry the skin barrier, pouch and skin very well to prevent any trapping of moisture.</p> <p>Use a pouch covered with fabric or cover it with a cotton lining.</p> <p>Put the pouch outside the Diaper.</p> <p>Topical treatment: Apply an antifungal cream or powder when changing the appliance.</p> <p>Make sure that the cream is well penetrated to prevent interference with the stoma product adhesion.</p> <p>When applying antifungal powder, fix it with a dab of water or alcohol-free skin sealant.</p> <p>Antifungal powder is preferred to antifungal cream.</p> <p>In severe cases, the prescription of systemic antifungals may be required.³⁹</p>	<p>Patients at risk of developing fungal infection:</p> <ul style="list-style-type: none"> • Under antibiotic therapy; • Immunosuppressed. <p>Continue the use of the antifungal product seven days after the disappearance of clinical signs of fungal infection.</p> <p>Allergic reactions sometimes result from a misuse of accessories.³⁸</p>


Stoma complications

Complications	Description	Management	Precautions
 <p>Allergy Allergic reaction to one of the components of the stoma product.</p> <p>Usually the affected area corresponds exactly to the area covered by the allergenic component.</p> <p>Skin appears red, itchy, scaly and inflamed.</p> <p>Once skin sensitivity develops, it may become a chronic problem.</p>	Usually allergy to sealants, barriers, tapes, solvents, powders, pastes or pouch fabric or materials.	<p>Identify and eliminate the allergenic product.</p> <p>Allergy history</p> <p>Skin patch test to determine the allergen.</p> <p>If it is impossible to modify the stoma product, apply a layer of alcohol-free liquid skin protector.</p> <p>Avoid the use of accessories, unless absolutely necessary.</p> <p>If they are necessary, ensure they are used correctly (e.g., let the skin barrier wipe dry before placing the stoma product).</p> <p>Cover the area affected by allergy with a thin hydrocolloid and apply the stoma product over it.</p> <p>For severe cases, consult with a physician for possible topical steroid treatment.</p>	Allergic reactions sometimes result from a misuse of accessories. ³⁸
<p>Folliculitis Inflammation of hair follicles usually caused by staphylococcus aureus.³⁹</p> <ul style="list-style-type: none">• Erythema• Sometimes pustular lesions• Superficial or deep <p>(May extend to the hair bulb).</p>	<ul style="list-style-type: none">• Traumatic hair removal.• Shaving too closely.• Excessive rubbing and cleansing of the peristomal skin.	<ul style="list-style-type: none">• Review hair and pouching removal technique.• Reinstruct pouching removal technique.• Avoid blade-type razor; use of scissors is recommended.• Antibiotherapy.• Education.	Obviously observed in teenagers.
 <p>Hyperkeratosis</p> <ul style="list-style-type: none">• Thickened, peristomal skin, whitish to greyish• Stoma product adherence issue• Pain and bleeding may be observed	Too large cutting of the skin barrier.	<ul style="list-style-type: none">• Assess the cutting technique• Education• Increase oral fluids:• acidity, Vitamin C, cranberry concentrate• Increase urine acidity <p>Topical treatment:</p> <ul style="list-style-type: none">• Soak with a solution of water and vinegar (1:1).• Soak duration: 15 to 20 minutes.• Thoroughly rinse with clear water.• Repeat at each appliance change.• Vesicostomy without stoma product: once a day.	


Stoma complications

Complications	Description	Management	Precautions
 <p>This is partial necrosis and has already been addressed previously</p>	Partial		
 <p>Prolapse</p>	<p>Protrusion of the stoma through the abdominal wall in a telescopic fashion.</p> <p>Frequent in diseases of the small bowel, especially in the case of a loop ileostomy.</p>	<p>Reduction of the prolapse.</p> <ul style="list-style-type: none">• Lay the patient down.• Reassure the parents /caregiver.• Use a larger pouch to contain the stoma. <p>You need to modify the cut of the opening of the skin barrier by cutting radial slits to enable it to slip over the stoma. Important: Reseal the skin barrier once it is on the skin.</p> <p>Educate the family/caregiver: Parents or caregivers must be advised to contact the surgeon/stoma care nurse for reduction of the prolapse. Some prolapses cannot be reduced, but if the bowel is healthy and well-functioning, that is not a problem. If surgery presents a risk for the child, or if the child is booked for surgery in the near future, the prolapse may be left as is. It is important that the family knows when they should contact surgeon/stoma nurse.</p> <p>Tip: Use powdered sugar or Xylomethazoline 1% nose spray/drops on the prolapse, and then contact the stoma nurse/surgeon.</p>	<p>Caution: Check the colour of the prolapsed stoma. It should be red-pink. Make sure the bowel is still functioning as well.</p>
<p>Consult the surgeon urgently if:</p> <ul style="list-style-type: none">• the colour of the stoma is abnormal (Example: dark red).• the stoma is not functioning.			

Stoma complications

Complications	Description	Management	Precautions
 Bleeding	<p>Blood is seen in the pouch or is present on the skin at pouch change.</p> <p>Small amount of bleeding from the stoma is normal.</p>	<p>Local pressure.</p> <p>If superficial bleeding is not self-limited, apply direct pressure with cold compresses.²⁹</p> <p>Check the size of the opening of the skin barrier and assess the application and removal of the stoma product.</p> <p>Educate parents/caregivers about cutting of the opening and way to put on and remove the stoma product.</p>	

Peristomal skin complications

Complications	Causes	Management	Precautions
<p>Erythema with peristomal skin loss:</p> <ul style="list-style-type: none">• Crusting technique: Apply a thin layer of stoma powder followed by a layer of alcohol-free liquid skin barrier. Repeat the application 3-4 times.• Apply the stoma product as usual, with stoma paste if needed.			
<p>Erythema without peristomal skin loss:</p> <ul style="list-style-type: none">• Apply a mixture of stoma paste and stoma powder around the opening of the solid skin barrier.• Apply the stoma product.			
 Redness, erythema <ul style="list-style-type: none">• With or without loss of epithelium• Burning, tingling• Discomfort	<p>Potential causes:</p> <ol style="list-style-type: none">1. Use of a pre-cut opening that is too large or cutting an opening too large in the stoma product.2. Prolonged wear-time.3. Liquid and corrosive stools, (acid pH).4. Flat or retracted stoma in a skin fold.5. Fistula at the base of the stoma.	<ul style="list-style-type: none">• Check cutting technique. If inadequate, re-educate• Inform about the signs indicating that the stoma product must be changed.• The use of a flexible convexity can help prevent leakage of stool or urine under the skin protective barrier.• Conservative management with zinc oxide paste and gauze if the stoma cannot be pouched.• In the case of a fistula or when the erythema cannot be resolved, surgery can be considered.	<p>Make sure that the suture line is healed before applying a flexible convexity.</p>

Systemic complication

Complications	Signs and symptoms	Management
Dehydration	<ul style="list-style-type: none">• Crying without tears• Dry mucous membranes• Sunken fontanel• Dry diapers, Less diuresis > 1ml/kg/h• Irritability• Tachycardia	<p>Notify the doctor, replace fluid loss intravenously according to medical order:</p> <ul style="list-style-type: none">• Rectum: > 20 mg/kg/day• Colostomy: > 20-30 mg/kg/day• Ileostomy: > 40-50 mg/kg/day
Electrolyte imbalance Observed with ileostomy/ jejunostomy		<p>Regular blood work (electrolytes) and supplement as required (IV, oral or enteral)</p>

29 Husain & Cataldo, 2008; WOCN, 2011
30 WOCN Core Curriculum Ostomy Management, Wolter Kluwer, Phil, 2016, Ed. J Carmel, J Colwell and M. Goldberg p. 193
31 "Reoperation to resect the necrotic portion may be necessary if the bowel below the fascial level becomes necrotic and a new ostomy will need to be reconstructed." (WOCN p. 76)
32 Sung, Kwon, Jo & Park, 2010
33 Sung et al., 2010
34 C Lyon, 2001
35 Butler, 2009; Colwell, 2004
36 Bafford&Irani, 2013; Black, 2009; Butler, 2009; Jordan & Burns, 2013
37 WOCN Core Curriculum Ostomy Management, Wolter Kluwer, Phil, 2016, Ed. J Carmel, J Colwell and M. Goldberg p. 197
38 WOCN, 2010
39 C. Lyon 2009

Chapter 8:

Perianal skin breakdown and diaper dermatitis post-stoma closure

Following stoma closure the child may have loose, frequent stools for various reasons:

- antibiotic use;
- transanal surgery;
- colon resection; or
- the type of enteral/oral feeds.

In most cases, this will be temporary, but it still poses a concern for parents.⁴¹ When stool is mixed with urine, the skin pH and enzyme activity increase, resulting in a reduction of the normal skin flora.⁴² This breakdown in the perianal skin area needs to be avoided. The goal is to keep stool away from the skin by frequent diaper changes day and night.

Prevention and treatment of perianal skin breakdown

- Routinely protect perianal skin with a protective skin preparation containing zinc oxide or dimethicone. «Providing an occlusive barrier can protect the skin injury and promote healing». (Darmstadt & Dinulos 2000, Ghadially & al 1992)
- Observe a rigorous hygiene.
- Wash hands before and after performing perineal skin care.
- Change the diaper promptly when wet or soiled to decrease skin moisture and contact with urine and faecal enzymes.
- Assess perianal skin for skin irritation or infection with each diaper change, and implement therapeutic measures as soon as irritation is identified.
- Cleanse the skin gently with warm water and a soft cloth or hold the child’s buttocks under running water. A syringe may be used to flush the area. Pat skin dry, avoid rubbing. If soap is used, a mild and pH-neutral soap is recommended.
- When the baby passes stool, only clean what is soiled. Do not take the residual cream barrier away. Frequent or vigorous removal of barrier product can further traumatize damaged skin. «Some barriers are thick and stay on the skin after gentle cleansing. It is appropriate to remove only

- the soiled layer of barrier.» (Taquino, 2000)
- Re-apply the cream barrier, if needed.
 - The baby can be left without a diaper to facilitate air to the excoriated area and frequent assessments.
 - Do not use baby wipes. Some brands contain alcohol, perfumes or preservatives that may contribute to skin irritation and increase the risk for skin sensitization.⁴³
 - Avoid prolonged sitz baths, because they macerate the skin and alter the skin barrier function. If the infant is given a sitz bath, use mild soap with low pH.
 - Avoid topical products containing isopropyl alcohol, camphor, salicylates, boric acid, baking soda or benzocaine. «As a general rule, stick with products designed for babies. Avoid items containing baking soda, boric acid, camphor, phenol, benzocaine, diphenhydramine, or salicylates. These ingredients can be toxic for babies.» (Sparks D, 2017)
 - Antibacterial ointments are not necessary or helpful for irritant diaper dermatitis, as it is not associated with an increased number of bacteria.
 - Disposable diapers with absorbent gel materials are more absorptive and keep perianal skin drier than those without absorbent gel or cloth diapers.

Management of diaper dermatitis

Since the baby’s buttocks have usually never been exposed to stool, moderate to severe diaper dermatitis usually occurs. Diaper dermatitis, whatever the cause, is a source of great discomfort for the child, and it represents a major challenge for the family and caregivers.

- The parents will need to get specific education about diaper dermatitis. It is important to:
- identify and, where possible, eliminate the cause of diaper dermatitis;
 - put in place preventive measures;
 - use appropriate treatments;
 - put in place preventive and management protocols in order to standardize nursing practice; and
 - educate the caregivers and families.

When diaper dermatitis is observed, the first step is to identify the type of diaper dermatitis. The following table describes the appearance and management of the different types of diaper dermatitis.

Type of diaper dermatitis	Description	Precautions
 Contact irritant dermatitis	Skin is red, with or without epithelium loss.	With loss of epithelium: 1. Lightly dust denuded skin with skin barrier stoma powder to absorb moisture and provide a tacky surface to which a zinc oxide ointment can then be applied. 2. Apply a protective cream barrier. The skin barrier cream can be mixed with stoma powder to increase its absorption properties. 3. Dust the cream with stoma powder. Without loss of epithelium: Apply a thick layer of skin barrier cream or a liquid protective barrier. The liquid skin barrier should not be applied more than every 24-48 hours.
 Chronic diaper dermatitis	Observed in infants and children with chronic diarrhoea. Following surgeries affecting bowel function.	Same as for contact irritant dermatitis. Close follow-up with family to support them in this difficult period.

Chapter 9:

Anal dilation, incision and scar care management

Anal dilation

Anal dilation is a procedure often initiated two to four weeks following repair of an anorectal malformation or pull-through for Hirschsprung’s disease. One of the most common complications following this type of surgery is anastomotic stricture. This type of stricture responds well to prophylactic dilations, which are usually done with metal or plastic dilators, or a parent’s finger. Dilations are usually performed once or twice a day.

In most cases, parents are taught to do this procedure at home, although it has been suggested that weekly dilations by the physician can produce the same outcome.⁴⁸

Parents need to understand the importance of doing this procedure, even if they find it physically and emotionally difficult. Once shown how to perform the dilation, a return demonstration by parent/caregiver will provide them with an opportunity to build their confidence and receive support if they are having difficulties. Parents also need to be aware that initially they may observe small amounts of bright blood, which is normal. The size of dilators, frequency of dilations, schedule for increasing sizes and desired goal size will depend on the preference of the surgeon/facility.

This is often a two-person procedure, one to hold the child and provide distraction while the other does the dilation. The child is often more upset by being restrained than because of discomfort from the procedure. Clear instructions need to be given for the following:

- Where to obtain dilators if not provided;
- How often to do the dilations;
- What size dilator to use and when to increase size as determined by the surgeon. The formula for working out dilator size is weight x 1.3 + 7;⁴⁹
- Who to call if problems arise; and
- Once the final size has been reached, the child should be assessed by the surgeon.


Even after dilations are no longer required, these children should have regular, long-term follow-up. Many suffer from constipation and/or incontinence, and early intervention to promote social continence is important for this population.

Incision and scar care

After stoma closure, the parents must be informed about the care of the wound, signs of infection and when they should call the stoma nurse or consult the surgeon.

Some surgeons close the site of the stoma with sutures, while others let the wound heal by secondary intention. The same wound care principles apply as those for adults; however, the use of low-adherence dressings is recommended. The healing process is usually faster in children than adults, so they may present with hypertrophic scars. Parents must be informed that once the wound is closed, they should massage the scar with a skin emollient or apply a specialized silicone dressing. This will help to prevent and manage hypertrophic scars.

47 Rouzrokh, Khaleghnejad, Mohejerzadeh, Heydari & Molaei, 2010
48 Temple, Shawyer & Langer, 2012
49 Lane VL, 2017.

Type of diaper dermatitis	Description	Precautions
 <p>Diaper dermatitis complicated by <i>Candida Albicans</i></p>	<p>Erythematous plaques + peripheral desquamation and satellite pustules.</p> <p>Skin folds are involved.</p> <p>«Colonisation by <i>Candida</i> was significantly more frequent in children with diaper dermatitis as compared to those with healthy skin (perianal 75% vs. 19%)» (Ferrazzini, G. et al. (2003).</p> <p><i>C. Albicans</i> should be considered to be present and pathogenic when diaper dermatitis lasts for more than three days.⁴⁴</p>	<p>Topical antifungal cream, ointment or powder.</p> <p>When applying an antifungal cream, always put a barrier cream over it since antifungal cream has no protection properties.</p> <p>Apply antifungal product two to three times a day as prescribed. The protective barrier cream should be applied as many times as needed, but always on top of the antifungal product.</p> <p>Pursue the antifungal treatment seven additional days after the disappearance of visible signs of infection, since microscopic <i>C.albicans</i> may still be present.</p> <p>Caution: Liquid protective barrier should not be used in case of fungal infection.</p>
<p>Allergic contact dermatitis</p>	<p>Uncommon.</p> <p>Mild erythema and desquamation. Sometimes vesicles and papules.</p> <p>Observed after contact with specific allergens: paraben, lanoline, substances found in disposable diapers, detergents, etc.</p>	<p>Identify and remove the allergen product.</p>

For infants excreting high amounts of bile acids in their faeces, consider using oral or topical cholestyramine, which binds to bile acids.⁴⁵ Cholestyramine can be applied topically as an ointment and also be prescribed per mouth.

Skin barrier cream can be removed with mineral oil to reassess the skin, usually after 48 hours or according to clinical judgement. Keep in mind that routine complete removal of protective skin preparations is not necessary, and may irritate the skin.⁴⁶

In the case of severe skin inflammation, the use of hydrocortisone 1% ointment decreases the inflammation, but it is not recommended for prolonged use. It should be applied in a thin layer for no more than 2-3 days.

Whatever product is used for prevention or management, it is important to read the manufacturer’s recommendations to make sure that the product is applied correctly. Equally important is the use of a standardised approach by all the caregivers, while supporting the parents closely during this very exhausting period.

For more information, please visit: Cincinnati Children’s Colorectal Center. Instructions For Parents Of Children After A Colostomy Closure For The Management of Anorectal Malformations.

Link to <https://www.cincinnatichildrens.org>

41 Cincinnati Children’s Colorectal Center
42 Atherton 2001, Atherton 2004, Davies & al 2006, Lin & al 2005, Scheinfeld 2005, Visscher & al 2000
43 Fields & al 2006, Scheinfeld 2005
44 White & al. 2003
45 WOCN Pediatric Ostomy Care: Best Practice for Clinicians p. 70

Appendix

Educational tools references

American College of Surgeons “kit”: www.facs.org/education/patient-education/skills-programs/ostomy-program/pediatric-ostomy

References

- Al-Harbi & al Mucous refeeding in neonates with short bowel syndrome. *Journal of Pediatric Surgery*, Vol 34, No 7 (July), 1999: pp 1100-1103
- ASCN & PSNG Stoma Care Nursing Standards and Audit Tool For the Newborn to Elderly.
- AWHONN, Neonatal Skin Care, Evidence-based clinical practice guideline, 2007; 1-57
- Bolinger BL. A Teenager’s Ostomy Guide. Chicago: Hollister Inc., 1978
- Broadwell DC, Jackson BS. Principles of ostomy care. In: Bolinger BL. The adolescent patient. St-Louis: Mosby, 1982: 532-544
- Cincinnati Children’s Colorectal Center. Instructions For Parents Of Children After A Colostomy Closure For The Management of Anorectal Malformations. <https://www.cincinnatichildrens.org>
- Colwell JC & al Fecal and Urinary Diversions Management Principles Mosby 2004 p 223
- Erwin-Toth P.The effect of ostomy surgery between the ages of 6 and 12 years on psychosocial development during childhood, adolescence, and young adulthood. *J Wound Ostomy Continence Nurs.* 1999 Mar;26(2):77-85.
- Fernandes JD, Machado MCR, Oliveira ZNP. Clinical presentation and treatment of diaper dermatitis-part II] *An Bras Dermatol.* 2009; 84(1): 47-54
- Fiers, S et Thayer, D. Management of Intractable Incontinence in Urinary and Fecal Incontinence. Ch 9: p. 183-189.
- Forest-Lalande, L. Ostomies in Childhood : Psychological Repercussions. *The Link* (CAET). April 2004 p. 10-19
- Garvin G Caring for Children with Ostomies. *Pediatric Surgical Nursing. Nursing Clinics of North America.* Volume 29, number 4. December 1994 p.645-654 p
- Irving V Caring for he and protecting the skin of the


- preterm neonate. *J wound Care* 2001 253-256
- Jeter KF. These special children. Menlo Park, Calif: Bull Publishing, 1982
- Lau ECT & al Beneficial effects of mucous fistula refeeding in necrotizing enterocolitis neonates with enterostomies. *Journal of Pediatric Surgery* 51 (2016) 1914–1916
- Lalande L. et St-Vil D. Ostomies in Children Ostomy Canada Spring 2001
- Landmann, Linda A., When your ostomy patient is an adolescent. *J Enterostomal Ther* 1989; 16(2): 87-88
- Lane Victoria A et al. Pediatric colorectal and pelvic surgery. Case studies. CRC PRESS Taylor and Francis Group 2017
- Lask B. & al. Psychosocial sequelae of stoma surgery for inflammatory bowel disease in childhood. *Gut.* 1987 Oct;28(10):1257-60.
- Lyon C & Smith A Abdominal stomas and their skin disorders. 2001
- Lyon C & Smith A Abdominal stomas and their skin disorders. Second edition 2009
- Lyon C The Problem Stoma- peristomal skin problems June 2013
- Mayo clinic, Diaper rash, 2018. <https://www.drugs.com/mcd/diaper-rash>
- McIltrout, K. (Ed.). (2016). Assessment and Management of the Pediatric Patient. In *Wound, Ostomy and Continence Nurses Society Core curriculum Wound Management* (pp. 158-175). Philadelphia.
- Mohr LD Growth and Development Issues in Adolescents With Ostomies *J Wound Ostomy Continence Nurs.* 2012; 39(5):515-521
- Mohr LD. & al Adolescent Perspectives Following Ostomy Surgery A Grounded Theory Study *J Wound Ostomy Continence Nurs.* 2016; 43(5):494-498
- Mounier C. Pediatric stoma therapy. *Psychological care Soins PEDIATR Pueric.* 1996 Nov-Dec;(173):19-22

- Motta GJ. Life span changes: Implications for ostomy care. *Nurs Clin North Am* 1987; 22(2): 333-34
- Oranges T & al Skin Physiology of the Neonate and Infant: Clinical Implications. *Adv Wound Care* (New Rochelle). 2015 Oct 1; 4(10): 587–595.
- Pediatric Subcommittee of the Wound, Ostomy and Continence Nurses Society, 2010
- Richardson L, Banerjee S, Heike R (2006) What is the evidence in the practice of mucous fistula refeeding in neonates with short bowel syndrome. *Journal of Pediatric Gastroenterology & Nutrition.* Vol 43 Issue 2, p 267 -270
- Rogers V Managing Preemie stomas: More Than Just the Pouch *JWOCN* 2003;30:100-10
- Rogers, V.R. (2007.) Wound management in neonates, infants, children, and adolescents. In N.T. Browne, C.A. McComiskey, L.M.Flanigan, & P.Pieper (Eds), *Nursing care of the pediatric surgical patient* 2nd Edition (167-181). Sudbury, MA: Jones and Barlett Publishers
- Rouzrokh, M., Khaleghnejad, A. T., Mohejerzadeh, L., Heydari, A., & Molaei, H. (2010). What is the most common complication after one-stage transanal pull-through in infants with Hirschsprung’s disease? *Pediatric Surgery International*,26(10), 967-970. doi:10.1007/s00383-010-2648-8
- Schaffner, A. Pediatric Ostomy Surgery *J Wound Ostomy Continence Nurs.* 2010;37(5):546-548.
- Scheinfeld N. Diaper dermatitis: a review and brief survey of eruptions of the diaper area. *Am J Clin Dermatol.*2005; 6(5): 273-81.
- Spain document: To cite the Spanish Guide using Vancouver style: Cebrián Batalla ML, Guijarro González MJ, Martín Romero C, Martínez Cano A, Sánchez Muñoz E, Valero Cardona A. Guía de atención integral al niño ostomizado. Madrid: Coloplast Productos Médicos, S.A; 2018
- Sparks, D. Home Remedies: Darn that diaper rash, Mayo clinic, March 17, 2017

- Temple, S. J., Shawyer, A., & Langer, J. C. (2012). Is daily dilatation by parents necessary after surgery for Hirschsprung disease and anorectal malformations? *Journal of Pediatric Surgery*,47(1), 209-212. doi:10.1016/j.jpedsurg.2011.10.048
- Weston WL & al. Diaper dermatitis: current concepts. *Pediatrics* 1980; 66:532-6
- WOCN Core Curriculum Ostomy Management, Wolters Kluwer, 2016
- WOCN PEDIATRIC OSTOMY CARE: Best Practice for Clinicians, 2011

Links:

- RNAO: (http://rnao.ca/sites/rnao-ca/files/Ostomy_Care_Management.pdf)
- Shadowbuddies.org: The Shadow Buddies Foundation is a children’s charity dedicated to providing support and knowledge to children with severe illnesses and disabilities. The foundation accomplishes this through unique programs designed to enhance the lives of children and adults by fostering compassion and awareness of differences with a line of 31 condition-specific “Shadow Buddy” dolls. Crafted from muslin and carefully researched to represent a child’s medical or emotional condition, Shadow Buddies offer seriously ill or medically challenged children the companionship of a friend “just like me.”



Section B:

Best practice guidelines for the psychosocial aspect of paediatric stoma care

This section presents best practice within the psychosocial aspects of paediatric stoma care. It includes recommendations concerning:

- Developing a therapeutic relationship with the child and family;
- How to adjust stoma care education to meet the individual needs of the child and family;
- The impact of a stoma in children and teenagers; and
- How children with a stoma and their families can approach daily activities.

Chapter 1:

Developing a therapeutic relationship with the child and family

One of the purposes of establishing a global set of guidelines is to enhance and support our work with the paediatric population and enable us to establish a valuable, therapeutic relationship with the child and family.

Parents and children are confronted with both the adjustment to the stoma and the implementation of stoma care. Children will respond differently, based on their age and developmental stage. So when building the therapeutic relationship with parents and children, there are a lot of factors to take into consideration in order to select strategies that match the child and family's situation.

One of your primary goals is to establish a relationship based on confidence and trust with the child and family, including siblings. The information you give **to the family must be accurate, comprehensive and individualised, respecting their beliefs and values.** This will reinforce the trust in the relationship.

“A therapeutic nurse-patient relationship is defined as a helping relationship that’s based on mutual trust and respect, the nurturing of faith and hope, being sensitive to self and others, and assisting with the gratification of your patient’s physical, emotional, and spiritual needs through your knowledge and skill.¹”



Chapter 2:

Adjusting stoma care education to meet the needs of the child and family

One of the many challenges when working in paediatrics is adjusting our approach not only to the patient, but also to his/her family. This also applies when the time comes for stoma care education. The education principles used with children are based on pedagogy, while those used for adults are based on andragogy (adult education).

Planning an education session

Before starting any care or education session, it is essential that you are familiar with the child's condition and overall treatment plan.

When planning an education session, it is equally important to take into consideration the circumstances in which the ill child and their family find themselves.

When people are in shock or denial, they are not ready to take in new knowledge and develop new skills. As much as possible, we must be sensitive to the readiness to learn on the part of the child and family.

When planning an education session, take into consideration the following factors:

- the developmental stage and age of the child; and
- the presence of any cognitive, physical or psychological barriers to learning.

Adjust your educational approach according to these factors. The chart below provides a list of recommendations for an effective education session.

1. Fostering therapeutic nurse-patient relationships Pullen, Richard L. Jr. EdD, RN; Mathias, Tabatha MSN, RNNursing Made Incredibly Easy!: May-June 2010 - Volume 8 - Issue 3 - p 4

“At each stage of development – from infancy, preschool and school age to adolescence and young adulthood – there are special considerations in stoma care.”

Recommendations for a successful education session

Recommendations	Rationale
Make sure you have enough time.	It is important to respect that people learn at different paces.
Check for readiness to learn and stage of grieving.	This will guide you in at what stage of readiness to learn they are.
Consider the child’s developmental stage according to age.	This will guide your teaching approach and ensure you use words and descriptions the child can understand.
Encourage the child to participate in his or her care.	This will promote his autonomy and make him part of the care
Use teaching aids.	This will help you adjust the education to the child’s developmental stage and level of understanding.
Suggest meeting with another child with a stoma or a parent.	While we can teach stoma care, a visitor can talk about what it is like to live with a stoma.
Provide different educational material (e.g. written, video, websites).	More than handing out material, explain stoma care – in the patient/family’s language, taking cultural issues into consideration, too. Make sure that the patient/family understand. An interpreter may assist you make sure that they go to appropriate websites.
Teenagers: Address the teaching to them first.	This will promote their feeling of responsibility in their care and autonomy. The teens’ priority for learning may be different than that of the parents.

What an education session should include

The contents of the education session should vary based on when you conduct the session. Here is an

overview of the topics that should be covered pre- and post-surgery as well as post-discharge.

Educational session contents

Recommendations	Rationale
Pre-surgery	<ul style="list-style-type: none">• Anatomy and physiology of the digestive/urinary system.• Planned surgery information/clarification.• Stoma appearance.• Examples of stoma products.• General stoma care.• Financial resources.
Post-surgery	<p>Visualisation of the stoma</p> <p>Stoma care:</p> <ul style="list-style-type: none">• Open the pouch.• Empty the pouch.• Close the pouch.• How to remove the pouching system.• How to measure the stoma.• Reproduction of the measure on the skin barrier paper.• Cutting of the opening of the skin barrier.• How to clean and dry the peristomal skin.• How and where to apply the stoma paste if needed.• How to apply the pouching system.• Look of normal peristomal skin.• When to change the pouching system.• Normal stool characteristics, odour, gas management.• Rectal discharge management in the case of a digestive diversion.• Medication: Can colour the stool/urine or cause odour. In the case of faecal stomas, it should be in liquid form, not slow-release because the absorption may be compromised when a medication is absorbed further in the digestive system.• Return to daily routine: Clothing, bath/shower, school, sports. Special attention should be given to culture sensitivity with hygiene practices, i.e. which hand is used in cleansing.• Complications: Signs of diarrhoea/constipation and management, signs of electrolyte imbalance and management. <p>Stoma and peristomal skin complications</p> <p>Stoma products: pouching systems and accessories.</p> <p>Nutrition according to age: introduction of new food, prevention of blockage.</p> <p>Professional, financial, psychosocial resources (e.g. youth camp).</p> <p>Stoma products supply centre.</p> <p>Surgeon and stoma nurse contact details</p>
Post-discharge	Follow-up with the patient and family to make sure they are caring for the stoma according to the recommendations and adjusting to their new reality.

“The post-period is a transition period where everyone has to adjust. Keep in touch with the families who need to be supported and guided in order to avoid inappropriate reactions.”

Post-surgery education

The contents of the education session should vary based on when you conduct the session. Here is an overview of the topics that should be covered pre- and post-surgery as well as post-discharge.

Where to begin

The very first step in stoma education is getting both the parents and the child (if age-appropriate) to touch the stoma. It’s important that they understand that it’s not painful.

When instructing parents, start with simple tasks. For example, you can first demonstrate how to open and empty the pouch. You can demonstrate by using a doll, and then on the child, and then the parents can perform the task under your supervision.

The same procedure can be followed when demonstrating a pouch change. Ideally, the parents and/or child (depending on the age) should master the procedure before being discharged from the hospital.

In addition to the basics of changing the pouch, the post-surgery education session should also address skin care. The child and parents must be taught about the characteristics of healthy peristomal skin, and know what to do in case a problem arises. They need to be taught how to clean the peristomal skin; how to dry it; and how to assess for any loss of integrity. They also need to understand when they should call the stoma nurse or the surgeon.

Tips regarding product selection

Make sure you have several brands of stoma products available for the child and parents to choose from, so they can decide which brand is the most appropriate.

You should also provide information about stoma accessories, although the philosophy is to use as few products as possible in paediatric stoma care in order to prevent any allergic reaction. The skin of most children heals very quickly, so there are less peristomal problems, assuming the stoma skin barrier is cut and applied correctly. However, it is important they are still aware of existing accessories.

Concluding the session

Once you have completed the education session, remember to provide the child/family with written material on the topics you have covered in the session. This way, they can go through the materials at their own pace when they get home. They are encouraged to ask questions if there is something they do not understand, or when they need more information.

At the end of each session, make sure that the child and parents have understood what they have been taught. One way to do this is to ask questions to verify what they have learned during the session. Ask questions like:

- What type of stoma does your child have?
- When should the pouch be emptied?
- Name two signs indicating that the pouching system must be changed.

It can also be useful to make a checklist to make sure that all the steps have been completed. This list also

helps ensure continuity of care from one caregiver to another. Here’s a sample checklist:

Teaching items	Demonstration by the stoma nurse	Practiced by patient/family	Mastered by patient/family	Comments
Open the pouch	April 4, 2018	April 5, 2018	April 6, 2018	
Empty the pouch	April 4, 2018	April 7, 2018	April 8, 2018	
Etc.				

Before starting another session, always ask if there are any questions or matters they need clarified.

Pre-discharge

Make sure children and parents have all the relevant information before they leave the hospital. This includes:

- The pouching system/accessories that have been selected with a prescription/contact with a supply company.
- Financial resources.
- Psychosocial resources, e.g. a youth camp for children with a stoma.
- Surgeon and stoma nurse phone numbers/emails.
- Written information about when they need to call the stoma nurse or the surgeon.
- Follow up-appointment date and time.

Post-discharge

After discharge, we recommend keeping in touch with the patient/family weekly. If the patient lives far away from the hospital, you can use online applica-

tions like Skype or FaceTime as an alternative to in-person visits. Use your clinical judgement to determine how often you should have contact with the family, either via phone calls or emails.

Keep in mind that, although the child and parents were comfortable with the education provided in the hospital, this might change when they get home. It is recommended that the stoma nurse meet with the child and parents at the follow-up appointment with the surgeon to ensure good communication with all involved.

Dealing with special challenges

You might encounter situations where the child or parent has some type of challenge or impairment that should be taken into consideration when conducting an education session.

In the chart below, we outline some recommendations for dealing with the most common types of challenges.

Recommendations for dealing with the most common types of challenges

Challenges	Recommendations
Visual impairment	<ul style="list-style-type: none">• Use material with large print.• Record audio instructions.• Use pre-cut skin barrier.• Recommend pouches with click-on signage assembly.• Use tactile signage of the location of the stoma, disc or plate.
Illiteracy, learning problems, hearing loss patients, patients who speak a different language	<ul style="list-style-type: none">• Use images and symbols for learning.• Use real objects and photographs to convey messages.• Record videos on a phone.• Involve speech therapists or sign language interpreters to convey the information.• Use translators in the appropriate language, or contact stoma associations in other countries.

If the family speaks another language, it might be necessary to get an interpreter. The Internet can be a valuable resource as well, but make sure the information is pulled from a reliable website.

Special tips for teaching children

Even at a young age, children can participate in their stoma care. For example, they can help by collecting the stoma supplies, drawing the pattern of the stoma on the skin barrier paper (that we have already drawn) and holding the pouch while the skin barrier is applied on the skin. By allowing children to be a part of their own stoma care, you can help them to feel proud and useful. They may begin to view it as a game, rather than something to be feared. You can also introduce role-playing, where the child can play the role of the stoma nurse and apply a pouch on the belly of a teddy bear or doll. Children like imitating adults, so this approach can be quite effective.

Young children typically know some parts of their body, but they have no idea about how they function internally. Using drawings can help children to identify internal parts of their body, e.g. the kidneys or bowel. You can use a mascot with a stoma to show how to empty the pouch, or use a colouring book that tells children what they need to bring to school. You can also read or tell a story about a child with a stoma. The key is to take advantage of the child’s imagination and use that as a tool for communicating with them about his/her stoma.

Some children do not express their feelings verbally. They feel more comfortable expressing themselves through puppets, dolls, or drawings. This can provide important information about whether further referrals are necessary i.e. child psychologist. In some countries, “child life specialists” are helpful for handling these situations. (For more information, see Section B, Chapter 3, ‘Impact of a stoma in children’).

Less formal methods of education

In addition to formal education sessions, you can arrange for the child and parents to meet other children with a stoma and their parents.

New parents always think that they are the only ones in this situation. Meeting other parents who have gone through the same experience can help diminish their anxiety and give them an opportunity to share their concerns. Listening to others’ stories may help them realize that they are not alone. They can see that there are ways to overcome the situation.

However, be careful when selecting other children or parents. It is important that the ones you select have a positive attitude and demonstrate it is possible to adjust to having a child with a stoma.

A special word about teenagers

When educating a teenager, we recommend instructing the teenager first, without the parents being present. There are several reasons for this approach.

Some teenagers are reluctant to talk about a part of their body that they don’t normally discuss with or show their parents. Some teenagers may act differently when their parents are present and may not express their true feelings. This approach also speaks to the teenager’s independence and can make it easier for them to accept the stoma as being a part of them.

After the session, encourage the teenager to share with his/her parents what they have learned. The same applies when visiting the stoma nurse or the surgeon/doctor. The teenager may prefer to be by himself and parents should respect this feeling.

Teenagers also like meeting people their own age with a stoma. They may want to look at others’ stomas; talk about clothes they wear; what activities they do; and which sports they play. Although we provide teenagers with this information as a part of educational sessions, it has more credibility when it comes from a peer in the same situation.

Additional resources

Here is a list of additional resources that can be useful in your education sessions.

Additional resources for education sessions

Additional resources/tips	Purpose
Step-by-step instructions with pictures/actual pouch at bedside.	Provides another method of learning
“Pouch Me Home” program (if available in country).	Outlines the necessary steps for the staff working with the family to accomplish before going home.
Pamphlets, magazines, colouring books and other materials available.	As a reference when needed.
Online resources.	Interactive programs for patient/family YouTube videos. E-learning through computer/smartphone (HIPPA secured). Caution: Ensure that the information is appropriate.
Patient/parents can videotape nurses changing a stoma product on their smartphones for later reference.	Facilitates the understanding and reproduction of the technique.
Inspirational letter to explain to friends what is a stoma.	How to explain to others about living with a stoma. https://www.stomavereniging.nl/community/informatie/werkstuk-spreekbeurt-stoma/ With a note saying that translation will be available

Chapter 3:

The impact of stoma surgery on the child and family

Stoma surgery has a tremendous impact on both the child with the stoma and the child's family. The entire family will experience a change in their everyday life, and the impact of this change cannot be underesti-

mated. In this chapter, we outline general factors to keep in mind regarding the impact of a stoma, as well as factors unique to the different age groups within paediatric care.

Neonates

Summary of developmental stages and impact

Characteristics of developmental stage	Parents' reaction	Nursing approach
<ul style="list-style-type: none">• Premature separation.• Primary bonding threatened.	<ul style="list-style-type: none">• A sense of unfairness.• Doubt.• Anguish and guilt feelings.• Fear that other pathologies might be discovered.	<ul style="list-style-type: none">• Clarify and reassure the parents.• Answer their questions.• Encourage the expression of emotions.• Suggest a meeting with other parents.• Demonstrate stoma care.• Involve the parents in the stoma care.

Working with the parents

Giving birth to a baby with a congenital defect, or a disease that requires formation of a faecal or urinary stoma, can be a difficult experience for new parents. They may find themselves with a baby who has been transferred to a special unit or a hospital outside of their community. The mother and her baby are separated, and their initial bonding is threatened. Parents may not understand why this has happened. And although they have been informed about the situation, they may have problems adjusting. Parents may feel a variety of emotions, including guilt, blame, shock and self-doubt. They may even question their ability to be good parents given the baby's medical condition.

According to the Kübler-Ross model³, there are five stages of grief: denial, anger, bargaining, depression and acceptance. This model is relevant because the parents are actually mourning the loss of the 'perfect newborn' they were expecting. Parents will go through these phases, so it is important to be aware of this in your approach and identify which stage of grief they are experiencing. They need to be reassured that they are not alone; that a professional stoma nurse will support them throughout the medical continuum – from the time the baby has a stoma until after stoma closure.

The nursing approach

Make sure the parents have a good understanding of the explanations given by the surgeon. It is important to answer any questions they may have, clarifying any misconceptions regarding the baby's condition and short- and long-term outcomes. The parents should have time to express their feelings in a supportive environment. Emphasis at this stage should be on the baby's positive progress. This will help the parents to avoid negative thoughts, which may only add to their anxiety.

Once the neonate's condition is stable, the parents should be involved in the baby's daily routine, such as diaper changing, skin care, supportive holding and skin-to-skin contact. This will help re-establish the initial bonding. Some mothers may want to breast-feed their baby. In such cases, the stoma nurse plays a vital role in reassuring these mothers, informing them that the stoma doesn't interfere with breast-feeding. Once they are comfortable with the every-day routine, they can begin to learn how to care for the stoma and change the pouch. They need to be constantly reminded that touching the stoma is not painful for the baby. They also need to know that the baby may cry, not because of any discomfort from actual stoma care, but because of feeling restricted when being held in connection with a pouch change. The stoma nurse should assist the parents to assess their ability, acknowledge any possible apprehension and support good technique. Involving both parents is recommended so that the stoma care does not rely on one parent. Parents can be introduced to other parents in the same situation.

The first two years of life

Summary of developmental stage and impact

Characteristics of developmental stage	Parents’ reaction	Nursing approach
<ul style="list-style-type: none">• Fear of new faces.• Mostly trust the parents.• Influenced by the messages received from their environment.	<ul style="list-style-type: none">• Parents are anxious about their child’s reactions.	<ul style="list-style-type: none">• Encourage the parents to stay at the hospital with their child.• Visit the child on a regular basis.• Establish a relationship based on confidence.• Give simple and clear information.• Transmit a positive message about the stoma.

If a stoma is created within the first two years of life, the child’s reactions must be taken into consideration to help them and their parents go through the situation as easily as possible. Parents may be sad and anxious when their child has to go through surgery. They may worry about the child’s reaction, anticipating possible distress from the experience. Some toddlers may be angry towards their parents because it was the parents who agreed to the surgery.

Working with the parents

Ideally, one of the parents should stay with the child while in hospital, as this will help reduce the child’s anxiety and promote a more positive experience. The parents’ positive feelings can encourage the child’s adjustment to the stoma. Parents also need to be aware of their child’s ability to cope with stressful situations.

The nursing approach

Usually, children of this age are apprehensive of new faces. They do not trust other people. For this reason, it is important to establish a good relationship with the parents, so that the child can observe this before you perform any physical care. Use play and physical contact to form a relationship with the child that involves more than invasive procedures.

It’s important for you to adjust to the child’s world and explain stoma care in words children can under-

stand. Remember that very young children live in the moment; so all explanations should be given immediately before the procedure (e.g. change of stoma product) and not several hours before. Children of this age are very influenced by their environment and the facial expressions of their family members and caregivers. It is important that the parent or caregiver has positive facial expressions and uses positive language throughout the care.

We highly recommend preparing everything you need before changing the pouch, and not prolonging the procedure. Distraction is a good way to change the focus, and parents can help here to create a calming atmosphere. Some negotiation may take place, but it must be a win-win experience. It is comforting for children to know that they may have their say, but you must use your clinical judgement and know where to put limits. Children need to know that certain rules apply and that they cannot control the entire procedure.

It is natural for children to explore their stoma and pouch, as they do with any other part of their body. The pouch may represent an interesting discovery because of its texture and sound. We advise parents to dress the child with a one-piece garment or a jumpsuit at this age, in order to reduce physical access to the stoma.

Pre-school children (2 to 5 years of age)

Summary of developmental stage and impact

Characteristics of developmental stage	Child’s reaction	Nursing approach
<ul style="list-style-type: none">• Need for independence and autonomy.• Genitalia discovery.• Potty training.	<ul style="list-style-type: none">• May interpret the stoma as a punishment.• Feelings of shame.• Castration fantasies.	<ul style="list-style-type: none">• Inform children according to age.• Encourage children’s participation in caring for their stoma.• Use of puppets and dolls.
Parents’ reaction		Nursing approach
	<ul style="list-style-type: none">• Afraid their child will miss classes.• Fear that the stoma product may leak at school.	<ul style="list-style-type: none">• Encourage the parents to avoid over-protecting their child.

Pre-school age is characterised by the child’s need for independence and autonomy. It is the age for genitalia discovery, and it is also within this period that children are potty trained. Pre-schoolers examine their body with great interest, begin to explore their genitalia; and are convinced that the part of their body that receives the most attention is the most important one. Children may have confused emotions and sometimes see the stoma as a punishment. Some may experience feelings of shame, and boys may have castration fantasies related to surgery.

Working with the parents

The parents’ feelings of guilt may lead to leniency in caring for the child. Other parents may react by becoming overly protective. In spite of the tendency to overprotect, parents must be encouraged to raise their child in a normal fashion. Rather than emphasising how their child is different, parents need to provide their child with a means of coping with the stoma. It

is important to give the parents the opportunity to express their own feelings in order to help them face reality in a positive way.

The nursing approach

For children between two and four years of age, the digestive and urinary systems represent a confusing ensemble. Children can name parts of their bodies, yet have little idea about their internal organs. Thus, simple and clear explanations contribute to demystifying any misconceptions children may have. It is important to pay attention to their fantasy world. Sometimes, children won’t express feelings directly, but puppets and dolls may help them to express their concerns and emotions.

Once the child is home, maintain contact with the family, so you can continue to offer support and advice.

School-age children (6 to 12 years of age)

Summary of developmental stage and impact

Characteristics of developmental stage	Child's reaction	Nursing approach
<ul style="list-style-type: none">• Competency developmental stage.• Intimacy is important.• Social role: being a student.	<ul style="list-style-type: none">• Children are concerned about their competencies.• They are destabilised.	<ul style="list-style-type: none">• Demystify the situation.• Reassure.• Encourage the parents to respect their child's autonomy.• Respect the child's intimacy.

This is the period when children acquire autonomy. They can now care for their own personal needs. Having a stoma created at this age may signify losing the control they have struggled so hard to gain. Before surgery the child was independent in his personal care. After surgery all of this changes. Suddenly, there is a stoma that attracts a great deal of outside attention. This can cause feelings of confusion and uncertainty. Some children even experience feelings of shame.

School-age is also a period where children begin to acquire competencies and abilities. In addition to being students, they have activities and a social role. It is an age where intimacy becomes important. Children begin to feel shy and do not like showing their genital parts.

Working with the parents

Parents are often more emotionally affected than the child. They may be anxious if the child misses school and worry about how the child will cope if the pouch leaks when they are away from home. They may feel guilty that they cannot protect the child from bullying. They often have great difficulty imagining that their child will be independent and successful in caring for the stoma.

Parents must be encouraged to promote their child's autonomy. Help them to see that involving the child in the care (e.g. helping to gather supplies; removing tape and skin barrier; tracing stoma size on the skin barrier backing) can give back some control in the child's routine. All the family members must find a reasonable balance in this regard. Depending on the child's level of autonomy, the goal should be for the

child to become increasingly involved in caring for the stoma. Use your clinical judgment to assess the child's competence and ability, and motivate the child to achieve autonomy.

The nursing approach

Once again, your role is to demystify and de-dramatize the situation. As mentioned previously, explain in clear, simple terms why the child has a stoma. Children of this age also live in a fantasy world, and it is important to give them clear explanations that they can understand. This will help to demystify false beliefs. Puppets and dolls may help children express how they feel. Some children will name their stoma, as it is a good way of adjusting and making the stoma a part of themselves.

Listen to them, their fears, and their apprehensions, so you can promptly diffuse any misconceptions they may have. This will also help you quickly detect any concerns they may have about school, such as the fear of leakage. Children are usually more resilient than adults, as they live in the present time. Thus, we recommend not informing children hours in advance when they need a pouch change. It's best to wait to just before the procedure. As mentioned previously, it is important to perform the procedure efficiently but smoothly, taking time for small breaks as necessary.

Caring for the stoma at school

As with all ages, school-age children should have access to at least two staff resources when going to school. They should also have extra clothes and stoma supplies available, either in their backpack or locker, in the event of an accidental leakage.

Adolescence

Summary of developmental stage and impact

Characteristics of developmental stage	Teenager's reaction	Nursing approach
<ul style="list-style-type: none">• Quest for autonomy and independence.• Highly concerned with their appearance, and reserved.	<ul style="list-style-type: none">• May be angry with the stoma, in denial.• Those who have been very sick may see the stoma as a rebirth.• Fear that the bag can be seen; that it smells or makes noise.	<ul style="list-style-type: none">• Try understanding the teenagers without judging.• Confront them with their occasionally aggressive attitude.• Respect the teenager's intimacy.• Be open to discussing sexuality issues.• Recognise the importance for teenagers to use social media as a way of seeking knowledge and reducing isolation.• Keep in mind that every teenager reacts differently. Some may choose to disguise their bag; others may show it off.• Refer to teenager support groups/youth camp.• Refer to a psychologist, if needed.• Recommend company or association booklets/magazines for teenagers.
Parents' reaction		Nursing approach
	<ul style="list-style-type: none">• Parents already have a child in adolescence crisis.• They are preoccupied with their child's future.• Split between overprotection, anxiety, culpability feelings.	<ul style="list-style-type: none">• Encourage the parents to avoid over-protection.

“Adolescence is generally a time of turmoil. Many consider it a war zone – a time and place in life marked by open rebellion and negativism. In fact, the teenagers in question may be demonstrating nothing more than reasonable physical and psychological growing pains.⁴”

Having a stoma during adolescence can be devastating to an adolescent’s self-esteem, especially in a society that focuses on body hygiene, appearance and success. In addition to their developmental crisis, adolescents must go through a situational crisis, which has a physical, psychological and social impact.

The physical impact

The most common reason that adolescents have stomas is inflammatory bowel diseases (IBD). These teenage patients must be informed after the surgery that they may experience accelerated growth and sexual maturation. In the same way, sexually mature adolescents may experience a regression during an acute period of their illness. Girls may lose their breast development and experience amenorrhea. Boys’ muscle strength may diminish.

Body image and sexuality

Adolescents with a stoma put a great deal of emphasis on the acceptance or rejection of their body. They may have difficulty dealing with their new mode of elimination and new body image.

They are often clumsy with their stoma care, carrying it out with feelings of disgust. Subjects like fertility, sexual potency, menstruation, and pregnancy pose uncomfortable questions for adolescents with stomas. Adolescents with stomas may feel that their capacity to attract a sexual partner is reduced. They may feel that, if they have problems liking themselves in their current condition, how can they ever hope to be loved by someone else? They may fear that their sexual performance has been altered. Some teenagers avoid the subject, refusing to consider themselves as sexual beings. Some of them will have sexual relations where the only goal is to test their ability to seduce.

The psychological impact

Hospital environment?

Hospitalised adolescents are more vulnerable. They are away from their home, family, friends and maybe their favourite pet. They don’t wear their usual clothes. Being hospitalised also means they have to stop their activities and miss school. All of this represents a challenge to their identity.

While at the hospital, adolescents may feel more dependent. They may feel that they have lost control and decisions are being made for them, which leads to feelings of increased vulnerability. During the hospitalization, adolescents must undergo physical examinations and manipulations that may embarrass them. They may be examined by members of the opposite sex and in the presence of others in the room.

How they cope

Reactions to this perceived loss of control vary from adolescent to adolescent. Some may go through the entire hospitalisation period without reacting, trying to keep control of their emotions. Some won’t express their real emotions to the hospital staff, but will share with their parents. They may have emotional outbursts and rebel. Others will react in a completely opposite manner, becoming totally submissive and self-centric. They may feel sad, desperate, and fall into denial.

To face the loss of control of their eliminatory function, adolescents may develop several defence mechanisms. Some may react by refusing to recognize their limits. They may try to surpass themselves and do more than they should, such as having their pouch stay in place longer than prescribed, acting as if they don’t have one. When they react in this way, they are trying to affirm their independence and defy authority, which is all part of the adolescence experience.

Factors impacting their response

Adolescents tend to adjust better if the stoma is temporary and they know it is only for a limited, defined time period. Adjustment is not so simple when the stoma is permanent, since its impact on their life will be long-term. You may also encounter adolescents who have temporary stomas, but for a prolonged period of time due to complications. It’s important that you are aware of all of these circumstances so you can help the adolescent adjust to their specific situation.

The circumstances surrounding the surgery will also have an impact on the adolescent’s adjustment. An emergent surgery could mean that the stoma is a sudden change. However, a planned surgery (i.e. due to a chronic illness) may represent a delivery, a rebirth, and the hope for a better quality of life.

The social impact

Within the family

Adolescents may feel they are different from other family members and worry about being rejected. Because of them, their parents often have to miss work; family activities are compromised; and siblings receive less attention from their parents. They may feel they are a burden for their family, and that they have no value.

Rebellious emotions can arise, such as, “Why is this happening to me?”. Those emotions may lead to the parents or siblings feeling guilty. Some parents will react by overprotecting their child. Parents may find it difficult to recognise and accept their child’s new competencies, especially after an illness or a surgery for a stoma and may react by overprotecting him. Often parents of teens with Crohn’s disease and ulcerative colitis have spent so much time with a sick child that, once they have a stoma, the parents have difficulty letting the teen become independent.

Other parents will excessively promote the adolescent’s autonomy. This reaction may also have an adverse

effect on the adolescent with the stoma. If adolescents are left totally alone, without supervision or interest, they may feel abandoned and be scared that they have to deal with all these new responsibilities alone.

At school

Adolescents with a stoma may be preoccupied about how their peers will react. They fear rejection. However, sharing their condition with peers is a delicate issue. Some have decided to tell their friends about the stoma, only to regret this later when the friends have betrayed them. Hiding the condition may also be harmful.

Many of these adolescents have missed a lot of school because of illness and surgery, and as a result have to repeat school years. This means they are left behind their peers. This feeling of being left behind can lead to feelings of depression.

The nursing approach

You play an important role in helping teenagers undergoing stoma surgery. Provide step-by-step information about the planned surgery; the medical tests; the stoma; stoma products and resources; and share what the process of adjustment to a stoma is like. It is important to provide consistent information as they may test you to both ascertain your level of expertise and to reassure themselves.

Teenagers’ intellect may help them adjust to their individualised pathology. They can understand the normal physiology of the human body, as well as the consequences of their own pathology. Using visual aids, as well as abstract and theoretical explanations may help them to understand their condition more fully. Knowledge is a valuable tool to help with adjustment; one that will help reduce adolescents’ anxiety regarding their illness.

However, a word of caution is necessary. Some adolescents may intellectualise their illness and become preoccupied with learning more about their

disease process. Yet, their ability to understand their pathology may be superior to their ability to adjust to it emotionally. This can make a difference in their adaptation process.

Another factor to keep in mind is that adolescents, while assimilating the information we give them, can sometimes misinterpret it. It is important to validate what they really understand.

Adolescents may also elaborate on their own theories made of facts, imagination and emotions. This mixture may reflect their life experience.

At times, you may become an adolescent's special confidant. He or she may express feelings to you that they would not have expressed to their parents or friends. Adolescents with a stoma need to have someone they can rely on, someone who will not judge them, and someone who will give them the time they need to process what is going on. While providing emotional support is a critical part of our role, we must also be able to recognize our limits and refer to a psychologist when the adolescent shows signs of anxiety or depression.

Additional recommendations

Here are some additional recommendations when dealing with adolescents with a stoma:

1. Try to understand, without being judgemental

Although their physical and sexual maturity may change due to their illness, it is important to communicate with teenagers according to their age level. Before meeting with an adolescent, familiarise yourself with the child's age and maturity. Be aware that adolescents can react with a wide range of emotions. Let the adolescent know that you understand their feelings. Negative feelings may increase at home; for this reason, it is important that you continue to communicate with the adolescent after discharge, either by phone, email, or face-to-face contact.

2. Respect their intimacy and address sexuality issues

It is important to discuss the subjects of contraception and protection with them. Once again, a relationship based on trust and respect for the adolescent's intimacy will enable you to discuss this delicate subject with them openly, and help them maintain a positive body image.

Adolescents are uncomfortable with people entering their physical space. Although supervision is necessary when they're learning how to care for their stoma, you should supervise at an acceptable distance. To make

allowance for any shyness they may have about their body parts, encourage adolescents to take charge of the stoma care. Let them know that if they need help, they should be responsible for asking for it.

3. Help them interpret and deal with others' reactions

Adolescents might not always understand why their parents react the way they do to their illness or stoma. It is important for you to explain to them why their parents might become over-protective or stand-offish.

As mentioned earlier, some adolescents will feel the need to talk about their condition with their peers. Encourage them to find words that will demystify the situation in a simple and natural way, without going into details that will lead to embarrassment or disgust. Adolescent patients should be aware that physical changes might generate discomfort amongst others, especially in the younger adolescent. However, at the middle of adolescence, peers usually become more accommodating. They may even sympathise and admire the adolescent, especially if he or she demonstrates a positive attitude. Suggest that the adolescent carefully select a trusted friend and ask for feedback.

4. Recognise their need for support

Adolescents with a stoma may feel isolated, as if they are the only ones going through this. They probably don't know anyone else in the same situation. This is why it is so important to introduce them to other adolescents with a stoma. This gives them a network with whom they can share their concerns and exchange ideas/get advice regarding clothes, sporting activities, social life, etc. There is no doubt that the visitor with a stoma has more credibility than anyone else. It is essential for the adolescent with a stoma to meet others who have succeeded. This gives him/her hope, and hope is crucial to adjusting optimally.

In some countries, camps for young people with a stoma provide the opportunity to meet other adolescents experiencing the same situation – in a fun, non-judgemental environment. This gives them a chance to share their concerns and feelings, and hear solutions. These camps help dispel the feelings of isolation they may be experiencing, by giving them the opportunity to develop new relationships. This represents a positive direction.

5. Keep an eye out for signs of depression or anxiety

Be on the lookout for any signs of anxiety or depression, and be ready to ask for a psychological consultation, if necessary.

6. Help them plan for life with a stoma

Like everyone else, adolescents want to be able to contribute to society. Encourage them to set realistic goals, which take into consideration their capabilities as well as their limitations. Help them avoid such traps as:

- total denial of their limitations, which can lead to self-deception; or
- exaggeration of their illness, which lead to feelings of worthlessness and desperation.

Career guidance can also enable the adolescent to have realistic expectations concerning his/her future.

Caring for teenagers with a stoma is a challenge. It requires patience, availability and respect of their pace and capacity to adapt. It also calls for acceptances of who they are, without judgement and in spite of their attitude or behaviour. Most of all, we must help them adapt to their new condition, recommending a pouching system that is reliable, comfortable, discreet and, more than anything, secure.

3. See the Glossary for more information about this model.
4. Katherine Jeter, 1982

Chapter 4:

Daily activities with a stoma

With adult stoma care, research often shows that a patient’s ability to resume daily activities has a positive effect on their quality of life and ability to live a productive life post-stoma surgery.

When working with paediatric stoma patients, our experience also indicates that being able to resume daily activities has a positive impact on the entire family. It is usually possible for children with a stoma to return to usual daily activities. However, some

precautions must be taken. For example, we recommend emptying the pouch before putting babies in prone position, when hugging them, or when using child transport devices.

The following chart outlines some basic daily activities for children with a stoma, and the recommendations regarding stoma care when participating in these activities.

Summary of developmental stage and impact

Activity	Recommendations
Bath/shower	<p>May bath/shower with or without a pouch?</p> <ul style="list-style-type: none">• Inform the parents and patients that there is NO risk that water will enter inside the stoma. Dry the skin barrier and pouch immediately after the bath/shower.• Do not use oily soap, foam bathing, oil in bath. This interferes with the stoma product adhesion.• If soap is used, make sure to rinse the skin thoroughly and gently tap dry• A moisture barrier is available in some countries to keep wounds, dressings, and IV sites dry.
Swimming pool	<p>Always wear a pouch</p> <ul style="list-style-type: none">• The stoma pouch must be emptied before entering the pool.• Liquid skin barrier can be applied on top of paper-type skin barrier adhesive to waterproof it. Elastic barrier strips can secure the skin barrier.• Wear a belt or tight briefs/underwear under boxer swimsuits. Dry the skin barrier and pouch immediately after.• Suggest printed bathing suits instead of plain.• Smaller pouch/mini-pouch or stoma cap, if available.• Remember to protect the filter.
Clothing	<ul style="list-style-type: none">• Suspenders for boys to hold the pants.• One-piece, jumpsuit.• Teenagers should avoid wearing jeans or pants that are too tight.
School	<ul style="list-style-type: none">• Do a trial run with a half-day at the beginning.• Parents or teenagers should meet with the school nurse if available or another school resource depending on to the age of the child.• The time of return also depends on the method of transportation: walking, being driven in a car or bus (some children could have hour-long bus rides).• Keep school authorities and classmates informed.
Sports	<ul style="list-style-type: none">• Be cautious with contact sports – protect the stoma.• Use stoma shields/guards (bought or made by an occupational therapist)• Use stoma belts during sporting activities.• Wide hair bands provide good support.• Use of elastic barrier strips.
Sleep-overs	<ul style="list-style-type: none">• Bring extra stoma products.• Bring extra clothes.

Glossary

Abdominal wall defects
See ‘Omphalocele’ or ‘Gastroschisis’.

Anorectal malformation
Anus is absent or has an abnormal position. Anorectal malformation is a spectrum, ranging from very mild forms, such as perineal fistula, to more serious ones, such as a cloaca in girls. With more severity, a higher incidence of alterations or agenesis of sacral vertebrae, of associated genitourinary malformations, of flat perineum with little or no muscular development.¹ Imperforate anus is a type of anorectal malformation.

Antegrade continence enema
Antegrade colonic enema surgery (ACE) and Malone antegrade colonic enema (MACE) are surgical procedures that are intended for alleviating severe symptoms of constipation and faecal incontinence caused by ano-rectal malformations or conditions that have impaired intestinal motility as observed in Hirschsprung’s disease and spina bifida. The surgical procedure connects the end of appendix to the stomach surface creating a stoma through which a catheter can be inserted allowing flushing the bowel thus it can be emptied. (ref: <https://www.ouh.nhs.uk/patient-guide/leaflets/files/11729Penema.pdf>)

Anti-reflux valve
A valve incorporated in urostomy appliances. This valve stops the urine from going back into the kidneys once it has drained in the pouch.²

Bladder exstrophy
Bladder exstrophy is a rare birth defect in which the bladder develops outside the fetus. The condition is more common in males than in females. The exposed bladder and urethra result in the bladder being unable to store urine.³

Cloacal exstrophy
Cloacal exstrophy is the most serious form of bladder-exstrophy-epispadias complex (BEEC), in which the rectum, bladder and genitals did not fully separate as the fetus developed. These organs may not be correctly formed. The pelvic bones are more severely affected as well. The backbone and spinal cord may be affected, as well as the kidneys.³

Colostomy
Surgically created opening into any section of the colon.⁴

Constipation
Constipation occurs when intestinal passage of stool is inhibited (not by obstructive substances; see intestinal obstruction instead) by various factors that interfere with intestinal motility. These factors can include diet, (lack of) liquid uptake and liquid absorption, and other congenital and genetic factors. (ref: Medicine (Baltimore). 2018 May;97(20):e10631)

Convexity
Surface that is curved or rounded outwards: provide tension on the skin, flattening peristomal skin contours causing a stoma to protrude better. Can be integrated to the skin barrier or added.²

Crohn’s disease
Inflammatory bowel disease in which the inflammation may occur anywhere on the GI tract, from the mouth to the anus, and may be continuous or patchy.⁴

Developmental stages
Please refer to Erik Erickson’s stages of psychosocial development.

End stoma
Stoma that is created by dividing the intestine, bringing the proximal end of the intestine through the abdominal wall, and maturing the stoma once outside of the abdominal wall to attach to the skin.⁴

Enterocolitis
Enterocolitis is an inflammation of the digestive tract and comprise Enteritis (inflammation of the small intestine) and Colitis (inflammation of the colon). Enterocolitis is caused by infections of bacteria, viruses, fungi, parasites, or by other noxious agents that affects the inner linings on affected area in the intestine. Enterocolitis usually manifests in frequent diarrheal defecations. (ref: J Gastroenterol. 2003;38(2):111-20)

Familial adenomatous polyposis
Inherited disorder characterized by the development of multiple polyps in the colon or other organs. Development of cancer is nearly 100% within 15 years of the appearance of polyps, which usually occurs during adolescence.⁵

Fistula
Abnormal connection between two epithelium-lined surfaces.⁴

Folliculitis
Inflammation of a follicle, usually caused by Staphylococcus Aureus.

Gastroschisis
Gastroschisis is a defect in the abdominal wall, usually to the right of the umbilical cord, through which the large and small intestines protrude (although other organs may sometimes bulge out). There is no membrane covering the exposed organs in gastroschisis.⁶

Granuloma
Presents as friable tissue, usually in small, raised round shapes, scattered at the mucocutaneous junction.²

Hartmann’s procedure
The Hartmann’s procedure is the surgical removal of a diseased portion of the distal colon or proximal rectum with formation of an end colostomy, accompanied by oversewing of the distal colonic or rectal remnant. This procedure may be the first stage of a two-part operation, in which at a later date, the colostomy and the over-sewn remnant are reconnected.²

Hirschsprung’s disease
Absence of intraneural ganglion cells and hypertrophic nerves of the bowel which have created a functional partial or full obstruction.⁴

Hydronephrosis
Hydronephrosis is swelling of one or both kidneys. Kidney swelling happens when urine can’t drain from a kidney and builds up in the kidney as a result. This can occur from a blockage in the tubes that drain urine from the kidneys (ureters) or from an anatomical defect that doesn’t allow urine to drain properly.³

Inflammatory bowel diseases
See ‘Crohn’s disease’ and ‘Ulcerative colitis’.

Ileal conduit
A method of diverting the urinary (Urostomy) flow by transplanting the ureters into a prepared and isolated segment of the ileum, which is sutured closed on one end. The other end is connected to an opening in the abdominal wall.²

Intestinal atresia and stenosis
Intestinal atresia is congenital defect broadly used to describe the complete blockage or obstruction anywhere in the intestine. Stenosis refers to a partial obstruction of the intestines usually resulting in a narrowing of the intestinal lumen. Small intestinal or colonic atresia are usually caused in utero when an unexpected event decreased intestinal perfusion leading to ischemia of the respective intestinal segment, leaving the segment narrow and underdeveloped. (ref: <https://emedicine.medscape.com/article/940615-overview#showall>)

Intestinal obstruction
A partial or complete blockage of the large or small intestine.²

Intussusception
Process in which the intestine telescopes back on itself. The resulting blockage can result in bowel necrosis if left untreated.⁴

Jejunostomy
Surgically created opening into the jejunum.⁴

Kübler-Ross model
The Kübler-Ross model is popularly known as the five stages of grief, though more accurately, the model postulates a progression of emotional states experienced by terminally ill patients after diagnosis. The five stages are chronologi-

cally: denial, anger, bargaining, depression and acceptance.⁶

Laparoschisis
A condition characterised by a congenital defect in the anterior abdominal wall, often accompanied by protrusion of part of the small and/or large intestine.⁷

Liquid skin barrier
Acrylate copolymer or a cyanoacrylate clear film that can be placed on the peristomal skin to provide skin protection from stoma effluent, adhesive stripping or, in some cases, to seal the skin barrier.⁴

Loop stoma
A loop ostomy or stoma is a stoma where both the upstream (proximal) and downstream (distal) openings of the bowel are brought out through the same hole in the abdominal wall.⁸

Malrotation
An intestinal malrotation is an abnormality that can happen early in pregnancy when a baby’s intestines don’t form into a coil in the abdomen. Malrotation means that the intestines (or bowel) are twisting, which can cause obstruction (blockage).⁹

Meconium ileus
Meconium Ileus (MI) is a condition where the content of the baby’s bowel (meconium) is extremely sticky and causes the bowel to be blocked at birth. Most babies with meconium ileus (90%) have Cystic Fibrosis (CF) and it is this that has caused the sticky meconium.¹⁰

Mitrofanoff/Monti
Mitrofanoff is a surgical procedure in which the appendix is used to create a channel between the skin surface and the urinary bladder allowing the bladder to be emptied through this conduit and out

of the stoma. The Yang-Monti procedure is an alternative procedure to Mitrofanoff where (a part of) the transverse ileum is used instead to create the conduit. (ref: J Pediatr Urol. 2010 Aug;6(4):330-7)

Motility disorders
These disorders occur both due to abnormal intestinal contractions or when intestinal peristaltic movement is paralysed. Motility disorders can be acquired or congenital such as Hirschsprung’s disease. (ref: Semin Pediatr Surg. 2010 Feb;19(1):50-8)

Mucocutaneous junction
Intersection between the bowel mucosa and the skin.⁴

Mucocutaneous separation
Detachment of stomal tissue from the surrounding peristomal skin of the stoma and mucocutaneous junction.⁴

Mucous fistula
The end of a section of defunctionalised bowel is brought through the abdominal wall when a stoma is created.⁴

Necrotising enterocolitis
Necrosis of the mucosal and submucosal layer of the gastrointestinal tract. Potential causes are: immature gastrointestinal tract secondary to altered functions in motility, digestion, intestinal epithelium integrity, circulatory regulation, poor immunologic defense, colonisation of bacteria and feeding intolerance.⁴

Neurogenic bladder
Bladder dysfunction caused by neurologic impairment of the central and peripheral nervous system, which innervates the bladder.⁴

One-piece pouching system
Solid skin barrier and the pouch as one unit.⁴

Omphalocele
Omphalocele is an opening in the center of the abdominal wall where the umbilical cord meets the abdomen. Organs (typically the intestines, stomach, and liver) protrude through the opening into the umbilical cord and are covered by the same protective membrane that covers the umbilical cord.⁷

Parastomal hernia
Defect in abdominal fascia that allows the intestine to bulge into the parastomal area.⁴

Peristomal allergic contact dermatitis
Inflammatory skin response resulting from hypersensitivity to chemical elements.⁴

Peristomal fungal/candidiasis infection
Fungal rash that can occur beneath the skin barrier and/or beneath tape-bordered products and pouches.⁴ Fungal infection may also develop around vesicostomies.

Peristomal moisture-associated skin damage
Inflammation and erosion of the skin adjacent to the stoma, associated with exposure to effluent such as urine or stool.⁴

Posterior urethral valves
Urethral valves occur when a boy is born with extra flaps of tissue that have grown in his urethra, the tube through which urine exits the urinary tract. This extra tissue prevents the urethra from properly

carrying urine from the bladder to the tip of the penis and out of the body. When urine can’t be normally expelled from the body, the organs of the urinary tract (the kidneys, ureters, bladder and urethra) may become dilated, or swollen.¹¹

Pouching system
Products used to collect the stoma effluent, which provide a secure, predictable seal and protect the peristomal skin.⁴

Prolapse
A prolapse is a stoma that essentially telescopes out through itself, causing abnormal lengthening.¹²

Prune belly syndrome
Severe congenital malformation with absence of abdominal musculature that presents with wrinkly appearance of the abdominal skin and urinary tract anomalies.⁴

Pseudoverrucous lesions
Exuberant growth of benign papules that occur around a stoma when urine or stool irritates the skin, a type of chronic irritant contact dermatitis.⁴

Pyoderma gangrenosum
Neutrophilic dermatosis characterised by recurrent painful ulcerations that present as pustules that enlarge and open into partial or full-thickness wounds, sometimes with dark colour irregular borders and purulent exsudate. These painful undermined ulcerations progress rapidly.⁴

Retraction
Disappearance of stoma tissue protrusion in line with or below skin level.⁴

Skin barrier paste (Stoma paste)
An adhesive hydrocolloid mixture available in a tube and used to enhance the seal of the pouching system. Also used to fill in uneven areas around and near the stoma to facilitate the seal of the solid skin barrier.⁴

Skin barrier ring (Moldable ring)
An adhesive hydrocolloid washer used around a stoma to enhance the seal by providing additional solid skin barrier and/or to level out the area around the stoma.⁴ Can also be used to create flexible convexity.

Skin barrier strip paste (Moldable strip)
A band of adhesive hydrocolloid used to fit around a stoma to enhance the seal or to fill in an uneven peristomal area.⁴

Solid skin barrier
The interface between the skin and the pouch of the pouching system that provides the seal (adhesion) and protects the peristomal skin.⁴

Spina bifida
Myelomeningocele or «spina bifida» is a defect in the formation of the neural tube, which causes a spectrum of defects along the brain and spinal cord.⁴

Stoma nurse
Registered nurse specialised in the care of patients with a stoma. Some are called Enterostomal therapy nurses (ET nurses). These registered nurses are specialised in wound, stoma and continence care.

Stomal necrosis
Death of the stoma tissue resulting from impaired blood flow.⁴

Therapeutic relationship nursing
A therapeutic nurse-patient relationship is defined as a helping relationship that’s based on mutual trust and respect, the nurturing of faith and hope, being sensitive to self and others, and assisting with the gratification of your patient’s physical, emotional, and spiritual needs through your knowledge and skill.¹³

Typhlitis
Typhlitis refers to inflammation of a part of the cecum. It’s a severe condition that usually affects people with a weakened immune system. Typhlitis may also be called neutropenic enterocolitis, necrotizing colitis, ileocecal syndrome, or cecitis.¹⁴

Two-piece pouching system
A solid skin barrier with a mechanism that accepts the pouch.⁴

Ulcerative colitis
Inflammation of the large bowel limited to the superficial mucosal lining of the bowel.⁴

Ureterostomy
An opening in which the ureters may each be brought to the skin in two separate stomas or one ureter anastomosed to the other and a single ureter brought out as a stoma.⁴

Urostomy
Non-specific, general term used to describe urinary diversions.⁵

Vesicostomy
An opening is made through the suprapubic abdominal wall into the bladder and the bladder mucosa is sutured to the abdominal skin to create a small stoma which may have the appearance of a small hole.⁵

Volvulus
A twisting of a portion of the gastrointestinal track that can cause a blockage, impair blood flow, and damage part of the intestine.⁴

1. Spanish
2. RNAO: (http://rnao.ca/sites/rnao-ca/files/Ostomy_Care__Management.pdf)
3. MayoClinic.org
4. WOCN Core Curriculum Ostomy Management, Wolters Kluwer, 2016
5. WOCN Pediatric Ostomy Care, Best practice for Clinicians, 2011
6. Wikipedia.org
7. NIH US National Library of Medicine <https://www.nlm.nih.gov/>
8. StomaWise UK
9. KidsHealth from Nemours <http://kidshealth.org>
10. <http://www.uhs.nhs.uk>
11. <http://www.childrenshospital.org>
12. GI Society
13. Pullen, R.L., Mathias, T. Fostering therapeutic nurse-patient relationships Nursing Made Incredibly Easy!: May-June 2010 - Volume 8 - Issue 3 - p 4
14. www.healthline.com

Paediatric stoma care

Global best practice guidelines for neonates, children and teenagers

These best practice guidelines governing paediatric stoma care are presented in two sections. The first section highlights the clinical aspects of paediatric stoma care. The second section addresses the psychosocial aspects of care, including stoma education and the emotional impact of a stoma on this patient group. The guidelines also include a glossary where you can find definitions for many of the terms used in the guidelines, and a list of additional resources that might prove helpful in treating this patient group. The guidelines cover the full spectrum of paediatric age groups, from neonates to teenagers.

Coloplast is the proud sponsor of the 'Global paediatric stoma care best practice guidelines, and has facilitated the process of creating this document. All content has been developed exclusively by the Global Paediatric Stoma Nurses Advisory Board (GPSNAB) with no involvement from Coloplast.